



A Rare Case Report- An Incidental Finding of Isolated Unilocular Splenic Hydatid Cyst

**Shubham Satyaprakash Gupta^{a†}, Sangita Jogdand Shinde^{b‡},
Raju K. Shinde^{a*} and Shweta Pandey^{c†}**

^a Department of Surgery, Jawaharlal Nehru Medical College, Sawangi (M), Datta Meghe Institute of Medical Sciences, Wardha, Maharashtra, India.

^b Department of Pharmacology, Jawaharlal Nehru Medical College, Sawangi (M), Datta Meghe Institute of Medical Sciences, Wardha, Maharashtra, India.

^c Department of Pathology, Jawaharlal Nehru Medical College, Datta Meghe Institute of Medical Sciences, Sawangi (M), Wardha, Maharashtra, India.

Authors' contributions

This work was carried out in collaboration among all authors. All authors read and approved the final manuscript.

Article Information

DOI: 10.9734/JPRI/2021/v33i52B33625

Editor(s):

(1) Dr. Aurora Martínez Romero, Juarez University, Mexico.

Reviewers:

(1) Marius Preda, Victor Babes University of Medicine and Pharmacy, Romania.

(2) Ahmed Kamal Dyab Haemaei, Assuit University, Egypt.

Complete Peer review History, details of the editor(s), Reviewers and additional Reviewers are available here:

<https://www.sdiarticle5.com/review-history/77293>

Case Study

Received 22 September 2021

Accepted 27 November 2021

Published 02 December 2021

ABSTRACT

Splenic Hydatid Cyst is a very rare presentation with less than 5% of total incidences of Cystic Echinococcosis. It is usually due to spread of cysts from other regions leading to secondaries. Primary isolated splenic hydatid cyst without involvement of any other organs is even rarer. We report an unusual case of a female who presented as Abnormal Uterine Bleeding (AUB) with an incidental finding of Isolated Splenic Hydatid Cyst with absence of involvement of any other organ. Patient underwent laparotomy and total splenectomy was done. This case report targets to report a rare case of incidental finding of isolated unilocular hydatid cyst of spleen and describes its management.

[†] Resident;

[‡] Professor and HOD;

^{*} Professor;

^{*}Corresponding author: E-mail: sg2638@gmail.com;

Keywords: Hydatid disease; abnormal uterine bleeding (AUB); isolated splenic hydatid cyst; unilocular cyst; echinococcosis; splenectomy.

1. INTRODUCTION

Spleen involvement in cases of Hydatid Disease is very rare, and isolated unilocular splenic hydatid cyst is even less common and is rarest of rare, that to without any significant related complains or symptoms. Most commonly involved organs in Hydatid disease is liver followed by lungs. Surgery remains the mainstay of treatment. We present here a very rare case of a 60 years old female with incidental finding of isolated unilocular splenic hydatid cyst with only complains of lower abdominal pain and abnormal uterine bleeding with no significant complains related to splenic hydatid cyst. We here discuss the incidence, clinical presentation, diagnosis, medical and surgical management of splenic hydatid cyst through this rare case report.

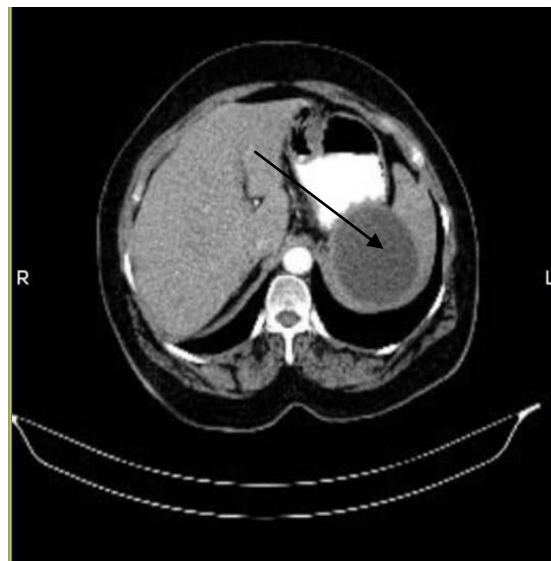
2. CASE REPORT

A 60 year old female presented in Gynecology OPD with complain of lower abdominal pain and post menopausal bleeding since 6 days. She had no history of fever, nausea or vomiting, no history of any gastrointestinal symptoms or any co-morbidity (diabetes, tuberculosis, sexually transmitted diseases and bronchial asthma). She was a newly diagnosed case of mild hypertension (130/100 mmHg) and was under anti-hypertensive medication (Tab. Amlo 2.5 mg BD).

On clinical examination, patient was moderately built with height of 155 cm, weight 65 kg and BMI of 27.1 with normal generalized condition. On per abdominal examination, it was soft, non tender, bowel sounds present in all four quadrants with no distension, guarding or rigidity. There was mild splenomegaly extending 2 cm below left sub costal margin, smooth in surface, firm in consistency, non tender and moves with respiration and no hepatomegaly.

Complete blood count revealed hemoglobin 13.5 g/dl, total white blood count $9,700/\text{mm}^3$, and differential leukocyte count as follows: neutrophil 55%, lymphocyte 40%, eosinophil 2%, monocyte 4%, and basophil 0%. Liver function tests, creatinine, blood sugar and BUN were normal. Abdominal Ultrasonography reported Splenomegaly with large well defined non-enhancing hypodense unilocular cystic lesion in the splenic parenchyma of size 8.9 x 8 x 7.5 cm

suggestive of Unilocular Splenic Hydatid Cyst. Contrast Enhanced Computed Tomography Scan of Abdomen and Pelvis was done which was suggestive of Splenomegaly with large well defined non- enhancing hypodense unilocular cystic lesion of size measuring 9.2 x 8.2 cm in infra splenic region of splenic parenchyma with no evidence of any daughter cysts ? Complex Splenic Cyst ?? Isolated Unilocular Splenic Hydatid Cyst with minimal endometrial collections noted with normal size and shape of uterus. There are no other cysts seen in the liver, lungs or any other abdominal or extra abdominal organ except spleen in sonographic and other radiographic studies.



(A)

Fig. 1. Arrow Mark in Image (A)- Contrast enhanced computed tomography scan showing Splenomegaly with large well defined non- enhancing hypodense unilocular cystic lesion of size measuring 9.2 x 8.2 cm in splenic parenchyma

Patient underwent splenectomy performed by dept. of surgery and diagnostic curettage for abnormal uterine bleeding (AUB) was done and pre operative histopathological report was suggestive of few glands in proliferative phase admixed with blood clots on scant endometrial curettage and thus, hysterectomy with bilateral salphingo-oophorectomy was performed by dept. of gynecology. Patient received prophylactic doses of Pneumococcal and Meningococcal Vaccines post operatively.

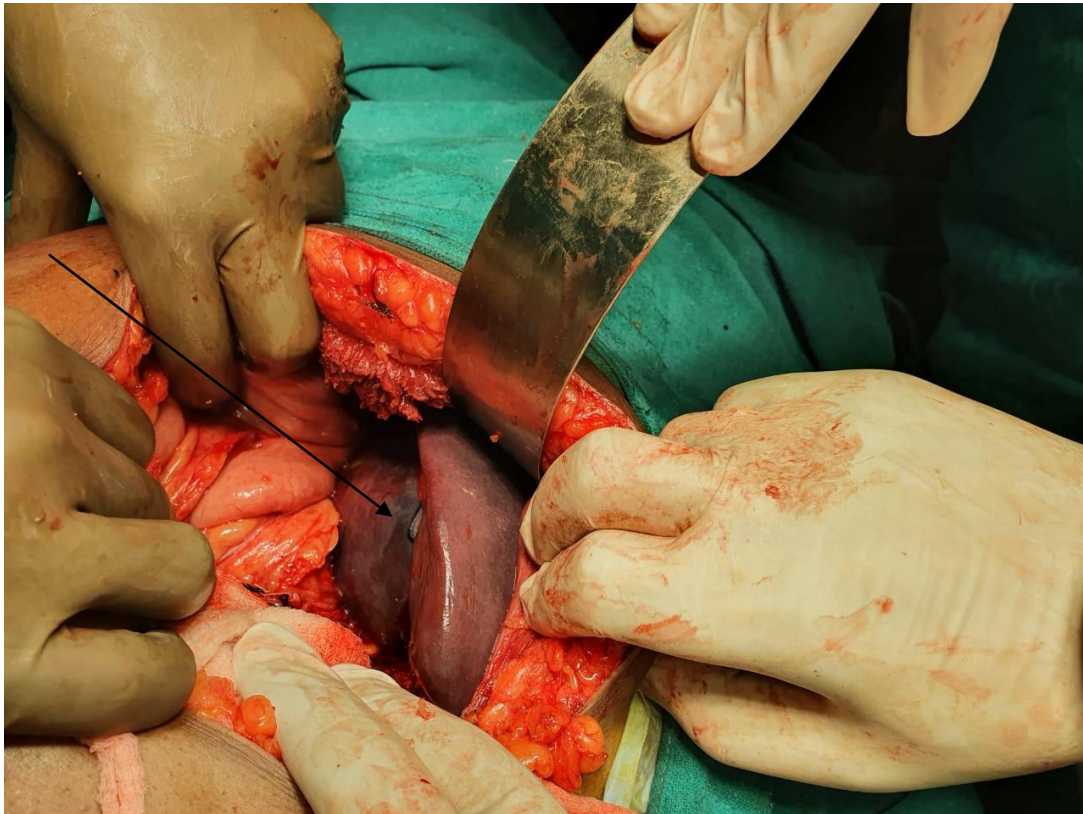


Fig. 2. Per operative finding showing enlarged spleen with splenic hydatid cyst

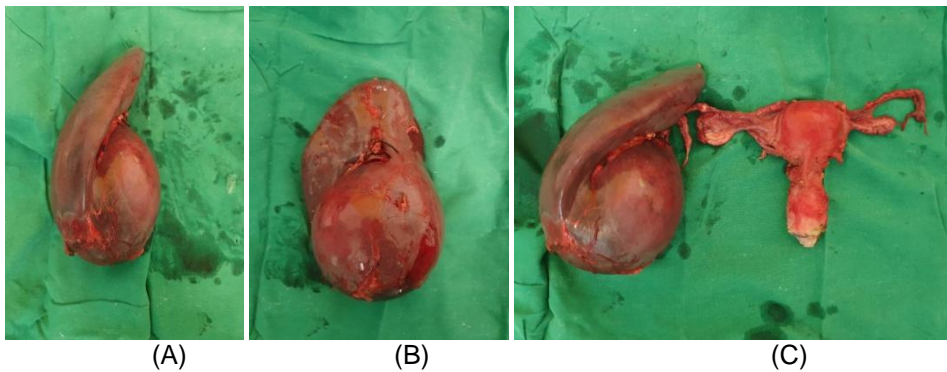


Fig. 3. Image (A) and (B) Shows gross splenectomy specimen with splenic hydatid cyst of size 9.2 x 8.2 x 8.1 cm; Image (C) Shows gross specimen of splenic hydatid cyst along with gross specimen of uterus with bilateral fallopian tube and ovaries

Section from splenic cyst showed cyst with laminated layers arranged in an onion peel like appearance and multiple cysts are also seen lined by an outermost fibrous layer consist of scolices and hooklets. Background is mostly clear and consists of few inflammatory cells. Histopathological features suggestive of hydatid cyst of spleen. Histopathology report of hysterectomy with bilateral salphingo-oophorectomy revealed adenomyosis of myometrium of uterus with bilateral ovaries and

fallopian tubes were unremarkable on histopathology.

Post operatively, the patient had an uneventful recovery and was discharged on the post-operative day fourteen. Oral Tab. Albendazole 400 mg bid for 3 weeks was given to the patient as a prophylactic measure against secondary hydatidosis for 3 cycles.

Patient was advised to follow up in surgery OPD after 4 weeks, repeat liver function test after

completion of course of Tab. Albendazole for 21 days. Patient was also advised to receive Pneumococcal Vaccine after 6 months,

Meningococcal vaccine after 1 year and booster dose of both Pneumococcal and Meningococcal Vaccine after 5 year.

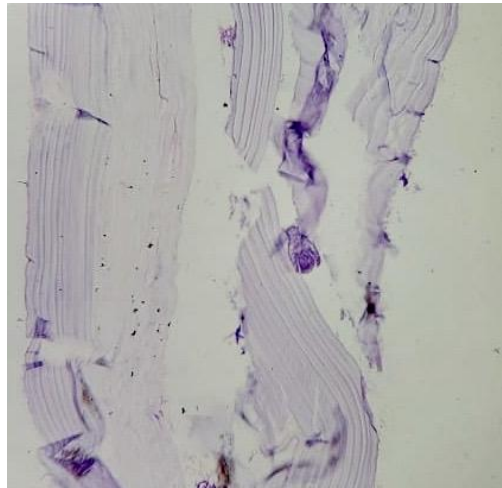


Fig. 4. Splenic Hydatid Cyst: laminated onion peel appearance of hydatid cyst [H & E; 10X View]

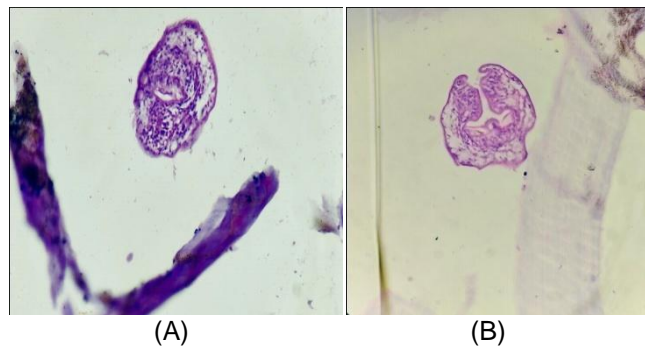


Fig. 5. A &B- Splenic hydatid cyst: Cyst is lined with outermost fibrous layer and consisting of daughter cysts and scolices with brooding capsules. [H & E; 40x]

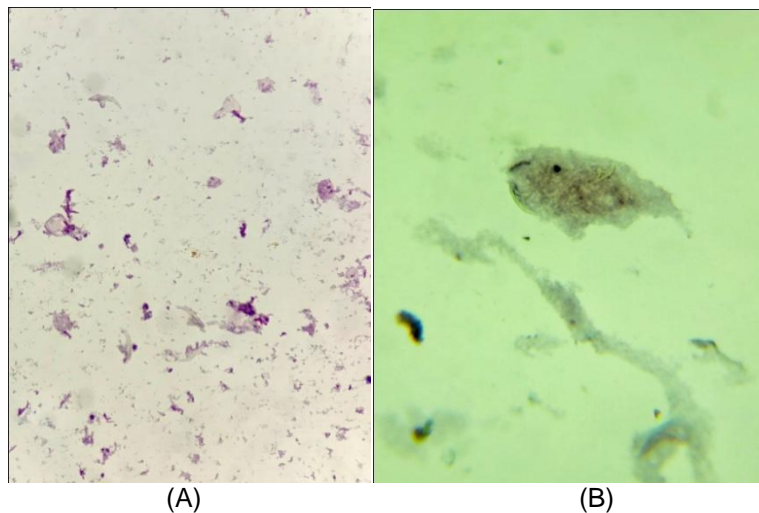


Fig. 6. A &B- Hooklets seen in background of clear fluid with bits of laminated membrane [Cytology; 40x]

3. DISCUSSION

Echinococcosis or Hydatid Disease is a major health issue worldwide. It is most commonly seen in areas where cattle and sheep are reared. This disease has got definitive and intermediate hosts. Dogs are considered as definitive hosts which passes egg in their feces. Development of cyst takes place in intermediate hosts like sheep, goats, camels, horses, cattle and humans. When egg is ingested by human, embryos escape from the egg and gets penetrated in intestinal mucosa which then enters in portal circulation and thus can involve any organ in the body[1]. Liver (60–70%) and lungs (10–40%) are found to be the most common sites of hydatid disease which acts as a first and second filter [2]. Commonest form of hydatid cyst disease is caused by *Echinococcus granulosus* where as alveolar type of hydatid cyst is caused by *Echinococcus multilocularis* [3]. Worldwide incidence of splenic hydatid cyst is 0.5-4% [4]. The incidence and prevalence of splenic hydatid cyst in India is 1.5% and 2.5% and that too highest incidence is found in Central India [5,6]. Rare sites for hydatid cyst disease are found to be spleen, thyroid, gall bladder, central nervous system, kidney, psoas sheath, retroperitoneal region, orbit [2]. Gupta et al., in their study revealed that incidence of cysts found in the liver are 55%–60%, in lungs are 30%, in kidney are 2.5%, in heart are 2.5%, in bones are 2%, in muscles are 1%, in brain are 0.5% and in spleen are 1.5% [5]. The cyst grows at the rate of 1 cm per year [7]. Splenic involvement is very rare since only 15% of cyst embryos enters systemic circulation, rest are trapped by liver and lungs. Primary infestation of spleen occurs through arterial route when eggs of parasite escape the liver-lung barrier. Splenic Hydatid Disease may also arise from retrograde venous route through portal circulation which bypasses liver and lung. Secondary splenic hydatid cyst can also occur by systemic dissemination or by intraperitoneal spread followed by rupture of liver hydatid cyst [8].

Approx 25-30% of splenic hydatid cysts are asymptomatic and symptoms are usually non specific [9]. It mainly presents with painful left sided abdominal mass with splenomegaly with or without fever, dull dragging ache, dyspepsia and dyspnea due to pushing of left hemidiaphragm [10]. In contrast to this, in our case, patient didn't have any symptom or sign except bleeding per vaginum. It was an incidental finding on radiological CT scan. The untreated splenic

hydatid cyst may complicate into secondary infection, inflammation, anaphylactic shock, intra abdominal rupture of cyst, acute abdomen, compression of other viscera or fistulisation to the bowel, mainly colon, rupture into the thorax leading to bronchopleural fistula, sympathetic pleural effusion etc. [7,11]. The Splenic Hydatid Cyst tends to grow and is vulnerable to trauma [12]. Intrasplenic pancreatic pseudocyst, abscess, epidermoid cyst, hematoma, and cystic neoplasm of spleen are some of the differential diagnosis of Splenic Hydatid Cyst [7].

Geographical background, history, personal history of contact with animal, physical and local examination or any hints towards diagnosis of unilocular isolated hydatid disease, blood investigations, radiological investigations (i.e. - USG, CT Scan) and histopathological examination of resected cyst are used for diagnosis of Splenic Hydatid Cyst [13]. Laboratory evaluation often yields non-specific data in case of unilocular isolated splenic hydatid disease. In absence of history and classical findings of multilocular hydatid cyst, serological tests in the form of IgE levels, IgM levels, serum immunoelectrophoresis, Casoni's intradermal skin test, indirect hemagglutination test, ELISA improves the sensitivity of the diagnosis. Raised IgE levels are a non specific indicator of active infection with parasitic organisms, while raised IgM levels may be a sensitive indicator specific to echinococcal disease [14]. Currently, the most reliable method is serum immunoelectrophoresis, with sensitivity of approx. 90-95% with 1 year positivity even after the organism has been eradicated [7].

Most definitive diagnosis for multilocular hydatid disease is based on abdominal USG and CT scan which have higher sensitivity and specificity [15]. Ultrasound has a sensitivity of approximately 90-95% [16,17]. It helps to determine, a solitary unilocular lesion or multiple well defined spherical cystic lesions with or without marginal calcification of spleen [18]. For follow up screening, USG is found to be more cost effective and valuable modality. CT has overall high sensitivity than ultrasound, with sensitivity rates of 95-100% [16,17]. CT scan of abdomen may show a cystic lesion with or without daughter cysts. CT is more accurate for localizing and determining the extent and wall calcification, segments involvement of the cyst [18]. In our case, there was no any relevant history or any relevant physical or local findings. It was only radiological tests which suggested

unilocular, isolated, asymptomatic hydatid cyst of spleen which made it difficult to differentiate from other cysts of that particular organ. Pre operative diagnosis can be made using Ultrasonography, CT or serological tests, but sometime cysts are diagnosed intra operatively only [19].

The gold standard treatment for Splenic Hydatid Cyst since decades is total splenectomy. To reduce the intracystic pressure, puncture and aspiration (PAIR) can be to drain the cystic fluid but splenectomy without puncturing the cyst is more preferable [20,21]. Apart from total splenectomy, partial splenectomy, partial pericystectomy, deroofting with omentoplasty and cyst enucleation are the various organ sparing surgery or techniques to treat Splenic Hydatid Cyst surgically. For uncomplicated hydatid cysts, laparoscopic approach has also been advocated. Newer methods like Puncture, Aspiration, Injection and Re-aspiration (PAIR) using hypertonic saline, 5% Cetrimide solution or 0.5% silver nitrate solution (scolicidal agents) before opening the cavities tend to kill the daughter cyst. Post operatively, medical treatment remains mainstay of treatment. Benzimidazole group of anti-helminthic drugs, i.e. - Albendazole 10–15 mg/kg/day for one month or Mebendazole 40–50 mg/kg/day for 3–6 months and Praziquantel 40 mg/kg/wk for 2 weeks are used pre and postoperative to decrease the chance of anaphylactic shock and to reduce the cyst wall tension. Post splenectomy, prophylactic vaccinations are given against *Streptococcus pneumoniae*, *Haemophilus influenzae* type b and *Neisseria meningitidis* organisms to reduce the risk of overwhelming post splenectomy infections (OPSI) [2].

In this present case, patient underwent total splenectomy (with inactivation of parasite intraoperatively by using cetrimide 5% as a scolicidal agent) followed by Tab. Albendazole 400 mg BD for 21 days as medical management. The 21 days course was repeated after 14 days without treatment to a total of 3 treatment cycles with monitoring of liver function test before initiating each 21 days course treatment cycle [22]. Vaccinations against organisms like *S. pneumoniae*, *N. meningitidis*, *H. influenzae* type b and influenza virus are strongly advocated and should be provided at least 2 weeks prior to surgery in elective cases (diseased spleen) or at least 2 weeks after the surgical intervention in emergency cases (normal spleen) [23]. In our case, patient received pneumococcal, meningococcal and influenza vaccine post

operatively after 2 weeks at the time of discharge and was advised to repeat pneumococcal vaccine after 6 months, meningococcal vaccine after 1 year and booster dose of pneumococcal and meningococcal vaccine after 5 years. Patient was also educated about OPSI and her immunocompromised state before discharge [22].

4. CONCLUSION

Splenic Hydatid Cyst is a diagnostic challenge especially in non endemic areas. But it should be considered in differential diagnosis of all cystic masses arising from spleen and with even a simple symptom of pain in abdomen alone. Splenic hydatidosis may become a challenging surgical issue if not assessed pre operative carefully. CT scan is the most accurate and sensitive investigation for establishing the diagnosis. Anatomical relations of the splenic hydatid cyst should be demonstrated properly before proceeding for surgery. Treatment for splenic hydatid disease may vary with each patient but surgical resection or total splenectomy would always remain the best curative procedure. The evolving or developing concept is towards spleen preservation surgeries with enucleation of the cyst to prevent overwhelming post splenectomy infections. Post operatively, medical or pharmacological treatment is essential for ensuring complete healing.

CONSENT

As per international standard or university standard, patients' written consent has been collected and preserved by the author(s).

ETHICAL APPROVAL

As per international standard or university standard written ethical approval has been collected and preserved by the author(s).

COMPETING INTERESTS

Authors have declared that no competing interests exist.

REFERENCES

1. Pezeshki A, Kia AB, Gholizadeh A, Koozhare A. An analysis of hydatid cyst surgeries in Tehran Milad Hospital, IRAN

- during 2001-2004. Pak J Med Sci. 2007;23:138-40.
2. Pukar MM, Pukar SM. Giant solitary hydatid cyst of spleen-A case report. Int J Surg Case Rep. 2013;4(4):435-437.
 3. C. Loussaïef, H. Ben Brahim, W. Ben Abdessalem, A. Toumi, A. Aouam and M. Chakroun. Primary Hydatid Cyst of the Spleen: Unusual Location International Journal of Case Reports in Medicine. 2013;2013.
 4. Splenic cysts: A review of 6 cases. Humphreys WG, Johnston GW, Br J Surg. 1979 Jun; 66(6):407-8.
 5. Gupta A., Kakkar A., Chadda M. A Primary intrapelvic Hydatid cyst presenting with foot drop and a gluteal swelling. Br. J. Bone Joint Surg. 1998;80B:1037-1038.
 6. Makkar M, Gupta C, Singh DP, Kaur S, Mahajan N. Giant Isolated Splenic Hydatidosis. Trop Parasitol. 2012;2:74-76.
 7. Miguel AC, Ernesto GV, Adriana AP, Raquel PA. A giant splenic hydatid cyst case presented with dyspnoea and fever. Medicrit. 2009;6:54-7.
 8. Shweta Rana, Shivani Kalhan, Sonia Hasija, Manmeet Kaur Gill¹ and Neha Garg Jain. Primary Hydatid Cyst of Spleen: A rare entity. International Journal of Biomedical and Advance Research. 2014; 05(08).
 9. Varghese C, Balakrishnan V. Hydatid Cyst of the Spleen: An Unusual Presentation. J Assoc Physicians India. 1979;27:1039-41.
 10. Col Hariqbal Singh, Maj Sumeet Arora. Primary Hydatid Cyst of the Spleen. MJAFI. 2003;59:169-170.
 11. Sahu SK, Srivastava R, Bahl DV, Sachan PK. Primary hydatid cyst of the spleen: A rare site of presentation. Internet J Surg. 2008;14:1.
 12. Nuraydin Ozlem. Traumatic rupture of a splenic cyst hydatid. Int J Surg Case Rep. 2015;7:112-114.
 13. Sedat Belli², Sami Akbulut¹, Gurcan Erbay³, Nazım Emrah Kocer. Spontaneous giant splenic hydatid cyst rupture causing fatal anaphylactic shock: A case report and brief literature review. Turk J Gastroenterol. 2014;25: 88-91.
 14. Bhandarwar AH, Katara AN, Bakshi GD, Rathod MG, Quaraishi AM. Splenic Hydatidosis. Bombay Hosp J. 2002;44:656-63.
 15. Merino NH, Morte AJ et al. Splenic hydatid cyst. A report 16 cases (Article in Spanish). EV ESP Enferm Dig. 1991;79:254-8.
 16. Current trends in the diagnosis and management of cystic hydatid disease of the liver. Dhar P, Chaudhary A, Desai R, Agarwal A, Sachdev A J Commun Dis. 1996 Dec; 28(4):221-30.
 17. Diagnostic evaluation and surgical management of hydatid disease of the liver. Safioleas M, Misiakos E, Manti C, Katsikas D, Skalkeas G World J Surg. 1994 Nov-Dec; 18(6):859-65.
 18. Dahnaya MH, Hanna RM, Ashebu S, Muhtaseb SA, El-Beltagi A, Badr S, et al. The imaging appearances of hydatid disease at some unusual sites. Br J Radiol. 2001;74:283-9.
 19. Abu-Eshy SA. Some rare presentations of hydatid cyst (*Echinococcus granulosus*). J R Coll Surg Edinb. 1998;43:347-52.
 20. Durgun V, Kapan S, Kapan M, et al. Primary splenic hydatidosis. Dig Surg. 2003;20:38-41.
 21. Dontigny L, Mercier C, Pagé A, et al. An unusual case of hydatid cyst. Can J Surg. 1976;19:23-5.
 22. Shams-UI-Bari, Arif SH, Malik AA, Khaja AR, Dass TA, Naikoo ZA. Role of Albendazole in the Management of Hydatid Cyst Liver. Saudi J Gastroenterol Off J Saudi Gastroenterol Assoc. 2011;17(5):343-347.
 23. Bonanni P, Grazzini M, Niccolai G, et al. Recommended vaccinations for asplenic and hyposplenic adult patients. Hum Vaccines Immunother. 2016;13(2):359-368.

© 2021 Gupta et al.; This is an Open Access article distributed under the terms of the Creative Commons Attribution License (<http://creativecommons.org/licenses/by/4.0>), which permits unrestricted use, distribution, and reproduction in any medium, provided the original work is properly cited.

Peer-review history:

The peer review history for this paper can be accessed here:

<https://www.sdiarticle5.com/review-history/77293>