



## **Diagnostic Value of Distal Forearm Densitometry for Osteoporosis; Alone or Add to Hip and Spine Densitometry?**

**Nasrin Moghimi<sup>1</sup>, Khaled Rahmani<sup>2</sup> and Mohsen Rajabnia<sup>3\*</sup>**

<sup>1</sup>Faculty of Internal Medicine, Kurdistan University of Medical Sciences, Sanandaj, Iran.

<sup>2</sup>Liver and Digestive Research Center, Kurdistan University of Medical Sciences, Sanandaj, Iran.

<sup>3</sup>Student Research Committee, Kurdistan University of Medical Sciences, Sanandaj, Iran.

### **Authors' contributions**

*This work was carried out in collaboration between all authors. Author NM designed the study, performed the statistical analysis, wrote the protocol and wrote the first draft of the manuscript. Authors KR and MR managed the analyses of the study. Author MR managed the literature searches. All authors read and approved the final manuscript.*

### **Article Information**

DOI: 10.9734/JPRI/2019/v27i330171

#### Editor(s):

(1) Dr. Syed A. A. Rizvi, Department of Pharmaceutical Sciences, Nova Southeastern University, USA.

#### Reviewers:

(1) Ali Al Kaissi, Orthopedic Hospital of Speising, Austria.

(2) K. Ramesh Kumar, S. V. S. Medical College, India.

Complete Peer review History: <http://www.sdiarticle3.com/review-history/48850>

**Received 15 February 2019**

**Accepted 24 April 2019**

**Published 11 May 2019**

**Original Research Article**

### **ABSTRACT**

**Background:** In most centers of the world, for diagnosing osteoporosis is used densitometry in hip and spine, but due to the high prevalence of distal forearm fracture and osteoporosis as its main etiology and on the other hand, evaluation of the distal forearm densitometry as an predictor indicator for axial osteoporosis, evaluate the diagnostic value of distal forearm densitometry for osteoporosis; alone and with adding to hip and spine densitometry.

**Materials and Methods:** This cross-sectional descriptive-analytic study was carried out on 250 patients referring to Sanandaj densitometry center from September 2017 to September 2018. For the studied subjects, BMD was performed by DXA method in three regions of hip, spine and distal forearm. Data were analyzed using independent t-test, fisher exact test, chi-square test and logistic regression test using SPSS v. 23 software.

**Results:** In this study, 68 cases (27.2%) in the spine region, 38 cases (15.2%) in the hip and 85 cases (34%) in distal forearm were osteoporotic. Based on the results of this study, using the

\*Corresponding author: E-mail: [Dr.rajabnia@outlook.com](mailto:Dr.rajabnia@outlook.com);

conventional method (hip and spine) in comparison with the studied method (hip, spine and distal forearm), 29 (11.6%) of those cases with osteoporosis are not diagnosed. Distal forearm densitometry alone in comparison with the conventional method has diagnostic sensitivity 74.66%, specificity 83.43%, positive predictive value (PPV) 65.88% and negative predictive value (NPV) 88.48%.

**Conclusion:** Adding distal forearm densitometry to conventional method significantly increasing diagnostic sensitivity of osteoporosis and would prevent misdiagnosis. Distal forearm densitometry can use as a predictor indicator of axial osteoporosis.

**Keywords:** Osteoporosis; densitometry; hip; spine; forearm.

## 1. INTRODUCTION

Osteoporosis is a common clinical condition that is associated with decreased bone density and increased risk of fracture, morbidity and mortality [1,2]. Regarding the high prevalence of osteoporosis, fracture and disability associated with it, high costs of treatment and rehabilitation, asymptomatic majority of patients, and post-emergence of serious and preventable disabilities and its complications, early diagnosis of osteoporosis using highly sensitive diagnostic tools are important [3,4].

Most centers in the world have used the densitometry of hip and spine (*conventional method*) to detect osteoporosis, but due to the high prevalence of distal forearm fracture and osteoporosis as its dominant etiology and on the other hand, the results of some studies have shown that the distal forearm densitometry is a good indicator for axial osteoporosis [5,6,7,8,9], it seems that the study of distal forearm bone density is very useful and valuable in addition to hip and spine.

Therefore, this study was conducted to compare the BMD diagnostic method in hip and spine (*conventional method*) with BMD in hip, spine and distal forearm (*studied method*) in the final diagnosis of patients with osteoporosis.

## 2. MATERIALS AND METHODS

This cross-sectional descriptive-analytic study was performed on 250 patients referring to Sanandaj densitometry center from September 2017 to September 2018. All subjects who had entry criteria were evaluated for measuring BMD by DXA in hip, spine and distal forearm after obtaining satisfaction.

Demographic information (age, sex, location and level of education) of patients was completed by checklist.

Individual weights were measured with a scale (100 g accuracy) and height using a meter (precision centimeters). Body mass index (BMI) was calculated by weight (kg) divided by height (m). BMD of hip, lumbar spine (L1-4) and distal was measured by hologic QDR 4500 Elite Bone Densitometer (USA).

Then, data from densitometry including bone density including osteopenia  $-2.5 \leq T\text{-score} \leq -1$  and osteoporosis  $T\text{-score} \leq -2.5SD$  were extracted based on WHO criteria. Data were analyzed using independent t-test, Fisher's exact test, Chi-square test, and logistic regression test using SPSS V.23 software. The significance level was considered to be 0.05 in all tests.

## 3. RESULTS

In this study, 250 patients were examined, of which 232 (92.8%) were women (155 menopausal women: 62% of the subjects and 66.8% female subjects) and 18 patients (7.2%) were male. The mean age of subjects was  $56.2 \pm 12.2$  years old (at least 28 years and maximum 84 years). 62 patients (24.8%) were illiterate, 138 patients (55.2%) had non-academic education and 50 patients (20%) had academic education.

136 patients (54.4%) urban and 114 patients (45.6%) were rural. The average body mass index (BMI) of the subjects was  $28.51 \pm 4.59$   $\text{kg/m}^2$  (min:  $17.48 \text{kg/m}^2$  and  $52.42 \text{kg/m}^2$ ).

In BMD, normal density, osteopenia and osteoporosis respectively were 29.6% (74 patients), 43.2% (108 patients) and 27.2% (68 patients) in spine, 42.8% (107 patients), 42% (105 patients) and 15.2% (38 patients) in hip, 38.8% (97 patients), 27.2% (68 patients) and 34% (85 patients) in distal forearm (Diagram 1).

In other hand, osteoporosis in spine, hip, distal forearm, spine and hip, spine and hip and distal

forearm, respectively were 15.2% (38 patients), 27.2% (68 patients) and 34% (85 patients) in spine, 30% (75 patients), 41.6% (104 patients) (Diagram 2).

subjects with osteoporosis were not diagnosed. Distal forearm densitometry alone in comparison with the conventional densitometry (hip and spine), its sensitivity, specificity, positive predictive value (PPV) and negative predictive value (NPV) respectively were, 74.66%, 83.43%, 65.88% and 48/88% (Table 1).

Based on the results on this study, using the conventional method in comparison with the studied method, 29 patients (11.6%) of studied

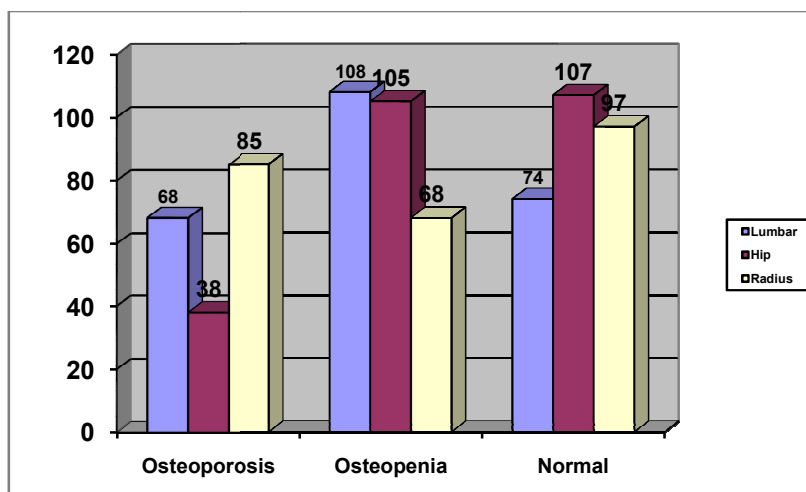


Diagram 1. Frequency distribution of densitometry status based on the area under study

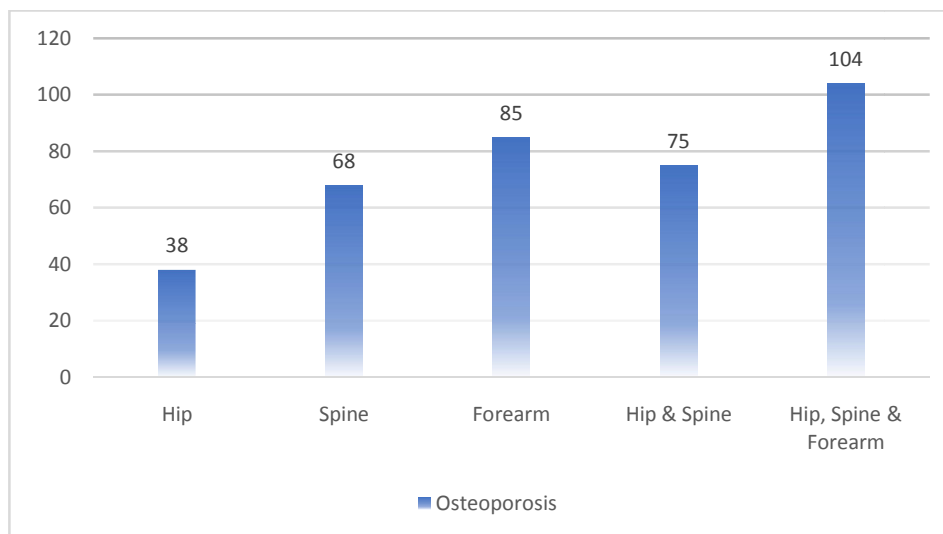


Diagram 2. Distribution of osteoporosis frequency according to the studied areas

Table 1. Osteoporosis diagnosis with distal forearm densitometry compared to conventional method

		Distal forearm	
		Osteoporosis	No Osteoporosis
Hip or Spine	Osteoporosis (n=75)	56	19
	No Osteoporosis (n=175)	29	146

**Table 2. Logistic regression results of the reviewing of relationship between demographic variables and osteoporosis event in positive cases in one of the 3 regions of Hip, Spine and Forearm**

Variable	The level of variable	Unadjusted		Adjusted	
		OR (95%CI)	P-value	OR (95%CI)	P-value
Age		1.116 (1.083-1.151)	<0.001	1.100 (1.062-1.146)	<0.001
Sex	Male	1	-	1	-
	Female	1.442 (0.552-3.767)	0.455	1.701 (0.434-6.668)	0.446
Education	illiterate	1	-	1	-
	non-academic	0.190 (0.10-0.38)	<0.001	0.610 (0.30-1.41)	0.3
	academic	0.070 (0.03-0.17)	<0.001	0.520 (0.14-1.99)	0.2
Address	village	1	-	1	-
	city	1.114 (1.079-1.144)	0.913	1.177 (0.629-2.201)	0.610
BMI		0.880 (0.82-0.93)	<0.001	0.870 (0.80-0.93)	<0.001

In this study, there was a significant relationship between age and BMI with the prevalence of osteoporosis in all regions (hip, spine and distal forearm) (P-value < 0.001). In other hand, there were no significant relationship between sex, education level and residence (urban or rural) with prevalence of osteoporosis in any regions (hip, spine and distal forearm) (P-value > 0.05) (Table 2).

#### 4. DISCUSSION

The main objective of this study was to compare the BMD diagnostic method in two regions of the hip and spine (*conventional method*) with BMD in three regions of the hip, spine and distal forearm (*studied method*) in the final diagnosis of patients with osteoporosis, which, according to the results of this study, using the conventional method compared to the studied method, 29 cases (11.6%) of those studied subjects who have osteoporosis were not diagnosed.

In the study of Amiri et al. conducted in 2016 in Tehran, BMD of the forearm BMD was compared with the hip and spine of the lumbar, that in 15 cases (12.5%), BMD in the distal forearm was estimated as osteopenia, while at the same time, it was reported in the hip and spine lumbar region as normal. In addition, in 10 cases (8.33%), the BMD of the distal posterior part of the forearm was reported, but the BMD of the hip and spine of the lumbar region was estimated in one case as normal and in 9 cases as osteopenia. This study showed that the addition

of distal posterior densitometry could increase BMD diagnostic sensitivity for osteoporosis [5].

A study by Zaman et al. in Pakistan in 2013 aimed at assessing the addition of BMD of the forearm BMD to the dental CT scan of the hip and spine in the final diagnosis of osteoporosis, it was shown that adding a lateral distal BMD leads to the addition of a diagnosis of the disease stage from normal to low bone density in 14% of cases and from low bone density to osteoporosis in 2% of cases and prevents from underestimated & missed diagnosis osteoporosis [9].

Based on available scientific evidence, early diagnosis of osteoporosis by using high sensitivity diagnostic tools is very important. It has been shown in many studies that osteoporosis in the distal part of the forearm may occur earlier than osteoporosis in other areas and it can be a predictive indicator for axial osteoporosis. In a study by Picard et al. in 2004 in Canadian, the value of peripheral densitometry (phalanx, proximal and distal bones) for diagnosis of osteoporosis was investigated in an axillary densitometry (hip and spine). In this study, the sensitivity and specificity of BMD in the phalanx were 0.79 and 0.83, in the proximal forearm, 0.84 and 0.79, and in the distal forearm, 0.90 and 0.75, respectively. Measuring the BMD of distal forearm had the most sensitivity in the diagnosis of axial osteoporosis (hip and spine) (diagnostic sensitivity was 0.90), while in our study, the diagnostic sensitivity and specificity of the distal forearm densitometry was 74.66% 83%

respectively [10]. This difference can also be due to racial diversity, lifestyle, age and sex of the subjects, study design, and the group studied in various studies and different measuring instruments. Therefore, in many cases that BMD (BMD in 2 regions of the hip and spine) is reported as normal, the reviewing of distal forearm can be useful in predicting bone loss in other areas, as well as preventing possible complications. On the other hand, failure to perform distal forearm densitometry leads to a lack of timely diagnosis of osteoporosis in the area and complications such as fracture. Studies have shown that distal forearm osteoporosis is a risk factor for fractures in this area. Kass et al. (2012) reported in a case control study on 35 patients with distal forearm fracture and 57 controls in women older than 50 years old who reported that the distal posterior osteoporosis could increase the risk of fracture in that area [11]. Hanusch et al., in 2016 in a case control study, on 61 men with distal posterior fracture of mild trauma and 59 men in control group showed that the BMD of the distal forearm in the case group was significantly lower than the control group [8].

Therefore, the conventional BMD (hip and lumbar) estimates the BMD of patients who have just a distal posterior region of the osteoporosis as normal (misdiagnosis & underestimate), which leads to complications of non-diagnosis and timely treatment such as the fracture in that area which it is accompanied by a patient's disability and significant financial costs for the patient and the treatment system.

Regarding the high prevalence of distal forearm fractures, associated morbidity and costs, it seems that screening and treatment of distal posterior osteoporosis is beneficial.

Finally, considering the possibility of osteoporosis in distal forearm, despite the normal BMD in the conventional method and possible complications due to its lack of recognition, including the fracture and the predictive value of distal forearm densitometry for prediction BMD in axial (including the hip and spine), BMD in 3 regions (hip, spine and distal forearm) is very helpful to increase the sensitivity of osteoporosis diagnosis.

Although in the conventional osteoporosis diagnostic method, BMD is performed in hip and spine, but by adding a bone densitometry in the distal forearm (BMD in hip, spine and distal

forearm) in the present study, it was shown that diagnostic sensitivity of osteoporosis would increase significantly, until there would be 29 cases (11.6%) misdiagnoses, regardless of distal forearm density. On the other hand, the distal forearm densitometry may be used as an alternative method in cases where BMD cannot be performed in hip and spine. Bone mineral density alone is not a strong index to diagnose high risk fracture in patients. The variety and confusing clinical and radiographic phenotypes made the task even harder.

## 5. CONCLUSION

Adding distal forearm densitometry to conventional method significantly increasing diagnostic sensitivity of osteoporosis and would prevent misdiagnosis. Distal forearm densitometry can use as a predictor indicator of axial osteoporosis.

## CONSENT

It is not applicable.

## ETHICAL APPROVAL

It is not applicable.

## ACKNOWLEDGMENTS

This study was extracted from thesis approved by Kurdistan University of Medical Sciences (ethical code of IR.MUK.REC.1396.373 Project code of 1396.373).

## COMPETING INTERESTS

Authors have declared that no competing interests exist.

## REFERENCES

1. Buckley L, Guyatt G, Fink HA, Cannon M, Grossman J, Hansen KE, Miller M. 2017 American College of Rheumatology guideline for the prevention and treatment of glucocorticoid-induced osteoporosis. *Arthritis Rheumatol.* 2017;69(8):1521-1537.
2. Gheita TA, Hammam N. Epidemiology and awareness of osteoporosis: A viewpoint from the Middle East and North Africa. *International Journal of Clinical Rheumatology.* 2018;134.

3. Gupta ED, Goh E, Gun SC, Hussein H, Shahril NS, Yeap SS, Sakthiswary R. Osteoporosis awareness among primary care physicians in Malaysia. EXCLI Journal. 2013;12:521-522.
4. Kadam NS, Chiplonkar SA, Khadilkar AV, Khadilkar VV. Prevalence of osteoporosis in apparently healthy adults above 40 years of age in Pune City, India. Indian Journal of Endocrinology and Metabolism. 2018;22(1):67.
5. Amiri L, Kheiltash A, Movassaghi S, Moghaddassi M, Seddigh L. Comparison of bone density of distal radius with hip and spine using DXA. Acta Medica Iranica. 2017;55(2):92-96.
6. Casagrande DJ, Morris RP, Carayannopoulos NL, Buford WL. Relationship between ulnar variance, cortical bone density, and load to failure in the distal radius at the typical site of fracture initiation. The Journal of Hand Surgery. 2016;41(12):e461-e468.
7. Egund L, McGuigan F, Önnby K, Giwercman A, Akesson K. High prevalence of osteoporosis in men with distal radius fracture: A cross-sectional study of 233 men. Calcified Tissue International. 2016; 99(3):250-258.
8. Hanusch B, Tuck S, McNally R, Wu J, Prediger M, Walker J, Datta H. Does regional loss of bone density explain low trauma distal forearm fractures in men (the Mr F study)? Osteoporosis International. 2017;28(10):2877-2886.
9. Zaman MU, Fatima N, Sajjad Z, Pirwani Z. Impact of adding distal forearm DXA to hip and spine measurements on DXA report. Journal of Biomedical Graphics and Computing. 2013;3(3):63.
10. Picard D, Brown J, Rosenthal L, Couturier M, Lévesque J, Dumont M, Dodin S. Ability of peripheral DXA measurement to diagnose osteoporosis as assessed by central DXA measurement. Journal of Clinical Densitometry. 2004;7(1):111-118.
11. Kaas L, Siersevelt IN, Vroemen JP, van Dijk CN, Eygendaal D. Osteoporosis and radial head fractures in female patients: A case-control study. Journal of Shoulder and Elbow Surgery. 2012;21(11):1555-1558.

© 2019 Moghimi et al.; This is an Open Access article distributed under the terms of the Creative Commons Attribution License (<http://creativecommons.org/licenses/by/4.0>), which permits unrestricted use, distribution, and reproduction in any medium, provided the original work is properly cited.

*Peer-review history:*

*The peer review history for this paper can be accessed here:  
<http://www.sdiarticle3.com/review-history/48850>*