

Morphologic characterization of *Sarcocystis* spp. histologically detected from the diaphragm and tongue of *Rattus norvegicus* and *Rattus tanezumi*

Cristina G. Cabanacan-Salibay^{1,2,*}, Florencia G. Claveria³, Hazel Anne Luyon-Tabo^{1,2}, Steven Paulo C. Salibay⁴, Augusto C. Sumalde⁵, Mario S. Torres^{1,2}, Julieta Zabal-Dungca⁶

¹Biological Sciences Department, College of Science and Computer Studies, De La Salle University, Dasmariñas, Cavite, Philippines

²Graduate Studies Department, College of Science and Computer Studies, De La Salle University, Dasmariñas, Cavite, Philippines

³Biology Department, College of Science, De La Salle University, Taft Avenue, Manila, Philippines

⁴Department of Biological Sciences, College of Arts and Sciences, Cavite State University, Main Campus, Indang Cavite, Philippines

⁵Institute of Weed Science, Entomology and Plant Pathology, College of Agriculture, University of The Philippines, Los Baños, College, Laguna, Philippines

⁶School of Science and Technology, Centro Escolar University, Mendiola, Manila, Philippines

Received:
August 25, 2019

Accepted:
March 17, 2020

Published:
July 30, 2020

Abstract

This study focused on the detection of *Sarcocystis* spp. in two species of rats, *Rattus norvegicus* and *R. tanezumi* collected from agricultural area in Dasmariñas, Cavite. This aimed to corroborate the presence of *Sarcocystis* spp. in different species of rats found in the agricultural area. Further the establishment of different *Sarcocystis* spp in *Rattus* spp. based on the parasite's morphologic characterization is also emphasized. Sixty-nine rats (36 *R. norvegicus* and 33 *R. tanezumi*) were collected through trapping. Individual rodent autopsy for host identification was performed by determining the morphological differences and external measurements prior to dissection. Tissue samples were examined for the presence of white rice-grain sized nodules. Morphological characteristics of the cysts, particularly the size, shape, and presence of protrusions were noted. Statistical analysis using ANOVA for the significant difference on the number of infected rats per species and across muscle type was done at $p \leq 0.05$. Infection in *R. tanezumi* was higher (48.48%) as compared to *R. norvegicus* (41.67%), the difference however was not significant. Sarcocysts burden was higher in the diaphragm in both rat species. Generally, higher parasite load was observed in *R. norvegicus*. In both rat species, tissue cysts ranged from spindle-shaped/fusiform to globular and oval-shaped. The sarcocysts in the diaphragm were more varied. Consistently observed in the tongue were globular-shaped sarcocysts while either fusiform- and globular-shaped sarcocysts in the diaphragm. These differences suggest infection with more than one species of *Sarcocystis*. Hence, the presence of *Sarcocystis* spp. confirmed the infectivity of the parasite to *Rattus* spp. Moreover, the different morphologic characteristics observed on *Sarcocystis* prove the possibility of different species of the parasite harboring the *Rattus* spp.

Keywords: Agriculture, Diaphragm, *Rattus* sp, *Sarcocystis* sp, Tongue

How to cite this:

Cabanacan-Salibay CG, Claveria FG, Luyon-Tabo HA, Salibay SPC, Sumalde AC, Torres MS and Zabal-Dungca J, 2020. Morphologic characterization of *Sarcocystis* spp. histologically detected from the diaphragm and tongue of *Rattus norvegicus* and *Rattus tanezumi*. Asian J. Agric. Biol. 8(3): 253-259. DOI: <https://doi.org/10.35495/ajab.2019.07.324>

*Corresponding author email:
ccsalibay@dlsud.edu.ph

This is an Open Access article distributed under the terms of the Creative Commons Attribution 3.0 License. (<https://creativecommons.org/licenses/by/3.0>), which permits unrestricted use, distribution, and reproduction in any medium, provided the original work is properly cited.



Introduction

Sarcocystis is a zoonotic protozoan apicomplexan parasite that causes the disease sarcocystosis whose intermediate-definitive host life cycle is attained through a prey-predator relationship (Jeffery et al., 2013; Gokpinar et al., 2014). The parasite reproduces sexually in the gut of the definitive host producing sporocysts containing infective sporozoites (tachyzoites) that are released with the feces and followed by ingestion of the parasite by the intermediate host to invade muscle tissues, thus completing the cycle (Fayer et al., 2015; Ahmed et al., 2016).

Humans may serve as definitive hosts in intestinal sarcocystosis caused by *Sarcocystis bovihominis* (*Sarcocystis hominis*) and *Sarcocystis suihominis* with bovine and pigs as intermediate hosts, respectively (Claveria et al., 2001; Ahmed et al., 2016). Intestinal sarcocystosis is transmitted by ingestion of sarcocysts-contaminated meat of intermediate hosts. Likewise, humans can serve as intermediate hosts in muscular sarcocystosis involving various final hosts such as cattle, bovine, bubaline, swine and other herbivores, carrying different species of *Sarcocystis* (Fayer et al., 2015). In muscular sarcocystosis, the parasite is transmitted by feco-oral ingestion of sporocysts by the definitive hosts. Both the muscular or intestinal infections are rarely serious and more of an opportunistic manifestation.

There are diverse animal hosts, including swine, birds, snake, rats, cattle, goats and monkeys, recorded in Southeast Asia commonly infected by more than 130 *Sarcocystis* spp. (Jeffery et al., 2013; Lau et al., 2014). However, sarcocystosis is an uncommon zoonosis of worldwide distribution. In most cases, they have been detected as an incidental finding at autopsy or necropsy. The presence of the parasite in diverse hosts in Southeast Asia is in congruence with the majority cases of the human and animal sarcocystis infections from this part of the world, particularly Malaysia and Thailand (Nichpanit et al., 2010; Latif and Muslim, 2016). In fact, there has been a report of large human outbreaks of sarcocystis infection in Malaysia (Fayer et al., 2015).

In the Philippines, *Sarcocystis* infections have been reported in buffaloes and bovine species (Claveria et al., 2005). The preliminary report of *Sarcocystis* was primarily identified in meat of a water buffalo consistent to this finding is the presence of *Sarcocystis* in the beef sold as ground meat) and muscles of water

buffaloes (Claveria et al., 2001). Other hosts that have been infected in the muscles by these protozoans are livestock like hogs, goats and chicken (Claveria et al., 2004). Higher infection has also been observed in muscle tissues of *Rattus* spp. (Claveria et al., 2005), one of the important intermediate hosts of this parasite. *Sarcocystis* spp. infection in both *R. norvegicus* and *R. rattus* muscles, particularly in the tongue and diaphragm was noted with thick walled sarcocysts containing numerous zoites.

Rats are pestiferous in nature and may be vital in effecting loss of agricultural profit. Because of their close association in human households, agriculture and commercial places, they become successful species to produce in any human dwellings and anthropogenic activities (Salibay and Claveria, 2005). They are considered efficient organisms and because of such nature, rats can flourish in mixed lands such as agricultural and residential areas. Thus, they are considered as successful species even with the presence of disturbance and human habitations (Salibay and Luyon, 2008). The most common rat species known to survive and inhabit especially near human dwellings and establishments are *R. tanezumi* and *R. norvegicus*. Their presence in these areas accounts for the possible transmission of zoonotic diseases like intestinal and muscular sarcocystosis to humans and other animals.

This study investigated *R. norvegicus* and *R. tanezumi* that are known to be invasive species and have close association to different anthropogenic establishments. This study also provides an update on the existing *Sarcocystis* data in the Philippines, their biology using rats as hosts, specifically *R. norvegicus* (the domestic rat) and *R. tanezumi* (the field rat) and their role in the transmission of *Sarcocystis* in human and animal meat infections.

Material and Methods

Collection and identification of rats

Stray rats were collected from agricultural land area in Burolo, the Eastern part of Dasmariñas, 3 kilometers away from the city center at 14.3292° N, 120.9439° E. (Figure 1).

Trapping of the rats using 20 spring-door wire traps with food bait was done late afternoon, and trapped rats were collected the following morning. In the absence of a rat, traps were left for 2-3 more days as rats may not approach novel objects in their surroundings at the first encounter (Rubio and



Sumalde, 1997). During the handling of the captured rats, leather gloves were worn to minimize the chances of being bitten or scratched. Each site was mapped out into subplots to avoid collection of rats at exactly the same plot.

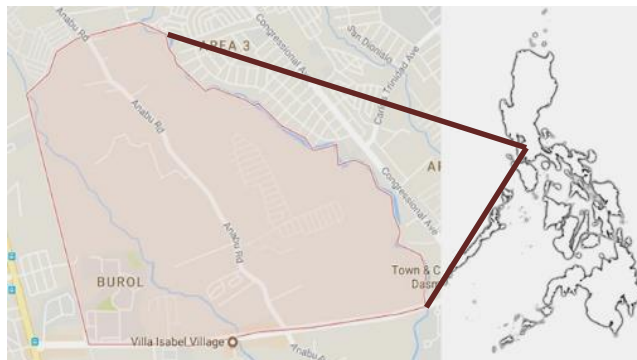


Figure-1. The Agricultural area where *Rattus* species were collected

Individual rodent autopsy for host identification was performed by determining the morphological differences and external measurements. Verification of pre-identified species was done at the Mammalogy Section, Zoology Division of the National Museum, Manila Philippines. In total, 69 rats (36 *R. norvegicus* and 33 *R. tanezumi*) were identified from the collection sites for a period of 12 weeks.

Handling of animals is in accordance to DA AO 40 series of 1999 and approved guidelines were adopted from the Philippine Association for Laboratory Animal Science Code of Practice for the Care and Use of Laboratory Animals in the Philippines (PALAS, 2002).

Collection of the infected tissues

The captured rats were individually-caged at the De La Salle University-Dasmariñas (DLSU-D) Laboratory Research Facility and were scheduled for euthanization to harvest their diaphragms and tongues. The captured rats were restrained by an improvised stabilizer covering only the body and limbs prior to euthanization. The rats were euthanized by 150 mg/kg sodium pentobarbital by intraperitoneal route (DA, 1999; PALAS, 2002; Hau and Van Hoosier, 2003; UP-IACUC Guideline, 2016). Confirmation of death was observed with rapid sedation followed by loss of consciousness to ensue death.

Tissue preparation and examination

The protocols Dubey et al. (2015) and of Bittencourt

et al. (2016) were followed in the preparation of the tissues. The dislodged tissues of diaphragm and tongue were individually stored in sealed containers and were processed within 24 hours post-collection. Tissue samples were examined for the presence of white rice-grain sized nodules indicative of sarcocystosis. To check for the presence of sarcocysts, thin muscle slices were mounted on glass slides and then teased lightly with fine needles and add a drop of saline solution.

Those tissue samples of the diaphragm and tongue suspected to have sarcocysts were fixed in 10% buffered formalin. Paraffin embedding method was done to prepare tissue paraffin blocks. This was further processed using the standard histologic hematoxylin and eosin (H & E) staining technique.

One section for each individual muscular tissue was analyzed. A photomicroscope hooked to a computer monitor was used in the examination of tissue sections at the Biology Laboratory, De La Salle University, Dasmariñas, Dasmariñas City, Cavite.

Statistical analysis

Morphological characteristics of the cysts, particularly the size, shape and presence of protrusions were noted. Statistical analysis using ANOVA for the significant difference on the number of infected rats per species and across muscular tissues and the standard deviation was done at $p \leq 0.05$. To compare the density of sarcocysts in the muscles, the number of the cyst per field of view of the slides (using LPO) was compared per rat species and per type of muscle.

Ethical standards

The procedure was approved by the Ethics Committee of the De La Salle University-Dasmariñas, Philippines (DLSU-DERC-2015-031A).

Results and Discussion

No macroscopic cysts were observed in the tongue or diaphragm of the *Rattus* species caught in the agricultural areas of Dasmariñas, Cavite, Philippines. However, microscopic examination of the tissues indicated positive for *Sarcocystis* spp. Of the 69 rats examined, there were more *R. tanezumi* (48.48%) infected with sarcocysts relative to *R. norvegicus* (41.67%) (Table 1). The infection rate between the rat species did not differ significantly.

Table-1. Number of *Sarcocystis* spp.-infected *Rattus tanezumi* and *Rattus norvegicus* caught in agricultural areas

Rat Species	n*	Number of Rats with Infected Muscles (%)			Number of Infected Rat per Species (%)
		Tongue	Diaphragm	Tongue & Diaphragm	
<i>R. tanezumi</i>	33	4.0 (12.12)	9.0 (27.27)	3.0 (9.09)	16.0 ^a (48.48)
<i>R. norvegicus</i>	36	2.0 (13.89)	10.0 (30.55)	3.0 (5.56)	15.0 ^a (41.67)
Number of infected rats per type of muscle (%)		6.0 ^a (8.70)	19.0 ^b (27.53)	6.0 ^a (8.70)	
Total number of Infected rats		31.0 (44.93)			

* Number of rats examined per species from 69 rats examined.

**Different letters indicate significant difference in the number of rats infected with sarcocysts based on different muscular tissues (tongue, diaphragm, tongue and diaphragm) or based on rat species (*R. tanezumi* vs *R. norvegicus*) using ANOVA at $p \leq 0.05$ level of significance.

While sarcocysts were detected in the tongue and diaphragm of both rat species, sarcocysts burden was markedly higher in the diaphragm than in the tongue regardless of the rat species ($p > 0.391$) (Table 2). Some rats of both species harbor the parasites in both tongue and diaphragm. Generally, higher parasite load was observed in *R. norvegicus*

Table-2. Mean sarcocysts per field of view of tongue and diaphragm of *Rattus tanezumi* and *Rattus norvegicus* caught in agricultural areas.

Rat Species	Mean Sarcocysts (Range)		
	Tongue	Diaphragm	Mean
<i>R. tanezumi</i>	1.14 (1-2)	1.25 (1-3)	1.21 (1-3)
<i>R. norvegicus</i>	1.0 (1)	1.46 (1-3)	1.33 (1-3)
Mean Sarcocysts (Range)	1.08 (1-2)	1.36 (1-3)	

The shape/form and measurements of sarcocysts from spindle-shaped or fusiform to globular to oval-shaped sarcocysts as well the configuration of the sarcocyst wall were variable (Figs. 2,3), suggesting infection with more than one species of *Sarcocystis*.

In both rat species, tissue cysts ranged from spindle-shaped/fusiform (Figure 2A, 2E, 2H) to globular (Fig. 2G; Figs. 3B, 3C, 3F) and oval-shaped (Figs. 2B, 2C, 2E, 2F, 2I, 2J; Figs 3A, 3D, 3E). Notably, the sarcocysts in the diaphragm were more varied ranging

from oval, elongated and globular forms. Those in the tongue, sarcocysts were either globular or oval in shape.

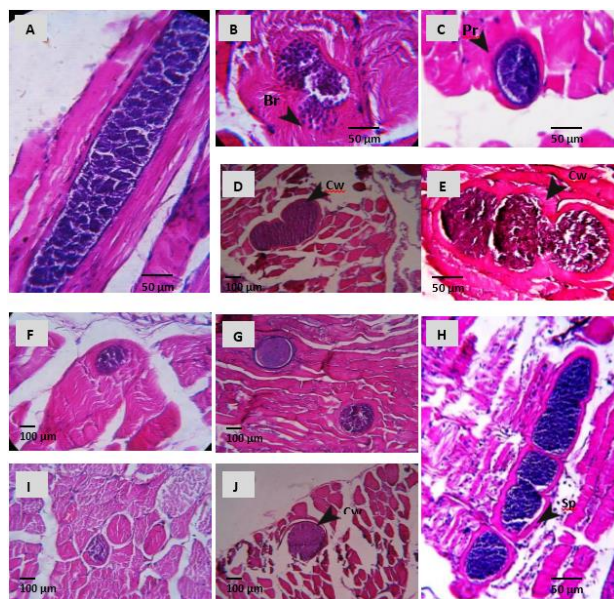


Figure 2. Photomicrographs of sarcocysts in the diaphragm muscle of *R. norvegicus* (A-F) and *R. tanezumi* (G-J).

Note fusiform, globular and oval shaped cysts, banana-shaped bradyzoites (Br), distinct protrusion (Pr), thin and thick cyst wall (Cw), and septum (Sp). Magnification, 400x (A, B, C, E, H); 100x (D, F, G, I, J).

The sarcocysts also display distinct villar protrusions (Figure 2C, 2F; Figure 3F) and striations (Figure 2C; Figure 3F) on their cyst walls. Although no measurement of thickness of the wall was taken to quantitatively distinguish them, visual observations showed varying thickness of the wall. Both the thin-walled and thick-walled sarcocysts observed in the two rat species were divided by septa forming a series of internal compartments and appearing in white lines. These sarcocysts contained the banana-shaped zoites of the parasite.

In general bigger tissues cysts in the diaphragm and smaller ones in the tongue were observed in both species. The forms of the sarcocysts in the diaphragm and in the tongue suggest that rats are infected with at two species, one with globular-shaped sarcocysts, and the other fusiform-shaped sarcocysts. Consistently observed in the tongue tissues were globular-shaped sarcocysts while either fusiform- and globular-shaped sarcocysts were observed in the diaphragm

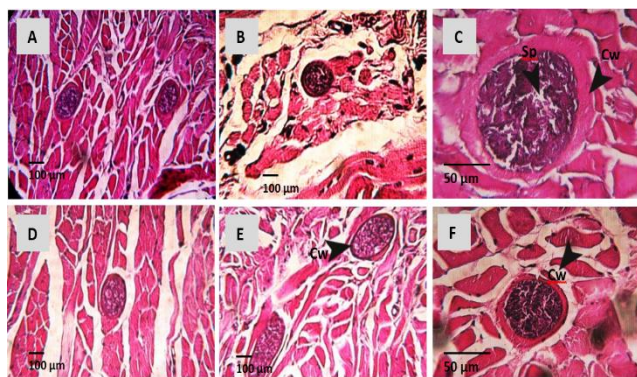


Figure-3. Photomicrographs of sarcocysts in the tongue muscle of *R. norvegicus* (A-C) and *R. tanezumi* (D-F).

Note globular and oval shaped cysts, septa (Sp), thin and thick cyst wall (Cw). Magnification, 400x (C, F); 100x (A, B, D, E).

Many studies worldwide have detected *Sarcocystis* in domestic animals, such as dogs and cats (Latif and Muslim, 2016), farm animals (Gokpinar et al., 2014; Bittencourt et al., 2016), wildlife (Dubey et al., 2015) and humans (Nichpanit et al., 2010; Lau et al., 2014; Fayer et al., 2015).

The presence of *Sarcocystis* spp in different species of rats have been recorded by Munday and Mason (1980) in skeletal muscles of rodents that served as intermediate hosts of this parasite. Among the *Rattus* spp. that harbor *Sarcocystis* spp. are the Eastern swamp rat (*R. lustreolus*); Southern bush rat (*R. fuscipes*) black rat (*R. rattus*) Norway rat (*R. norvegicus*); long-tailed rat (*Pseudomys higginsii*) and broad-toothed rat (*Mastacomys fuscus*). The findings in the present study, using *R. tanezumi* and *R. norvegicus*, confirmed the infectivity of *Sarcocystis* spp. in animals in the Philippines.

The presence of sarcocysts in rats is indicative of the role of rats in the completion of the life cycle of the parasite. Moreover, the role of the rats as a prey of many predatory animals (mammals, reptiles, birds) pave the way for the *Sarcocystis* spp. to reach their definitive host where their sexual cycle would be completed (Hu et al., 2012).

The observation on *Sarcocystis* distribution in the muscles of rodents in the current study is consistent with the previous reports elsewhere (Hu et al., 2012; Latif and Muslim, 2016), as well as in the Philippines (Claveria et al., 2005). The detection of both developing and mature sarcocysts indicates the active parasite transmission in the research site.

With regard to the species of *Sarcocystis* in rats, a

related study in Thailand (Jäkel et al., 1997) reported six *Sarcocystis* spp. in the skeletal muscles of wild rodents. Included were *S. singaporensis*, *S. villivillosoi*, and *S. murinotechis*, which showed a striated cyst wall at the light microscopic level, while *Sarcocystis cymruensis*, *S. sulawesiensis*, and *S. zamani* possessed smooth cyst walls. In the present study, the presence and absence of striation in some sarcocysts were also observed. Furthermore, the noted morphological variations (e.g. size, shape, and cyst wall) suggest that there are probably several *Sarcocystis* species present in one host (Latif and Muslim, 2016). Such morphological variations were in congruence with the characteristics of sarcocysts infecting the diaphragm and tongue muscles of the examined rats in the present study.

The detection of sarcocysts in the examined rats underscores the rats' role as intermediate hosts in the completion of the parasite's life cycle (Hu et al., 2012). In addition, the presence of these pestiferous animals within the agricultural areas where many farmers and other rural dwellers habituate reinforce the transmission of the parasite to domestic animals and pets (dogs and cats) and farm animals (cattle, water buffaloes, pigs, chicken). Hence, exposure of humans directly to infected rodents, or indirectly through animals infected by these rodents, pose risks of foodborne and waterborne zoonotic sarcocystosis. In this context, it can be said that the presence of sarcocysts-infected rats can possibly pose public health risk due to their proximity to human inhabited areas (Salibay and Luyon, 2008) where humans are likely to be infected opportunistically by *Sarcocystis* spp.

While the current study proved the presence of *Sarcocystis* spp. in *R. norvegicus* and *R. tanezumi*, the identification of the species of *Sarcocystis* cannot be done by the use of light microscopy alone. The observed variations in the length and width of the cysts in the present study may be related with the age of the cysts (Bittencourt et al., 2016) and cannot be used solely for the identification of the parasite. In addition, the histologic examination by light microscopy may allow the identification of thick wall and thin wall cysts, but they do not permit the differentiation of the species, even using high magnification which limits to 1000x. And since a full view of the cyst surface, which is an essential feature for the characterization of the cysts morphology (Dubey et al., 1989) was not microscopically obtained, this study did not attempt to identify the species of *Sarcocystis*. Hence, extensive

studies using more powerful microscopic technique and biomolecular analysis are needed to aid possible parasite identification present in *Rattus* spp. at the species level.

Conclusion

The presence of *Sarcocystis* spp. confirmed the infectivity of the parasite to *Rattus* spp. Moreover, the different morphologic characteristics observed on *Sarcocystis* proved that different species of the parasite harbor the *Rattus* spp. Hence, the role of rats in prey-predator relationship among organisms is suggestive of the significant spread of *Sarcocystis* spp. in other host animals, including humans. This poses the risk to transferring *Sarcocystis* spp infecting man through ingestion of contaminated meat, thereby increasing public health concerns, especially those within the vicinity of the agricultural areas where these rats dominate.

Acknowledgment

The researchers would like to thank the Biological Sciences Department, De La Salle University, Dasmariñas and Centro Escolar University laboratory technicians for the technical assistance in the dissection of the rats and the initial processing of the tissues.

Disclaimer: None.

Conflict of Interest: None.

Source of Funding: None.

References

- Ahmed AM, Elshraway NT and Youssef AI, 2016. Survey on *Sarcocystis* in bovine carcasses slaughtered at the municipal abattoir of El-Kharga, Egypt Vet. World. 9(12): 1461-1465.
- Bittencourt MV, Meneses IDS, Ribeiro-Andrade M, de Jesus RF, de Araújo FR and Gondim LFP, 2016. *Sarcocystis* spp. in sheep and goats: frequency of infection and species identification by morphological, ultrastructural, and molecular tests in Bahia, Brazil. Parasitol. Res. 115:1683–1689.
- Claveria FG, Cruz-Flores MJ and De La Pena C, 2001. *Sarcocystis miescheriana* infection in domestic pigs (*Sus scrofa*) in the Philippines. J. Parasitol. 87: 918-919.
- Claveria FG, San Pedro-Lim MR, Tan JE and Florez-Cruz MJ, 2004. *Sarcocystis capracanis* infection in Philippine domestic goats (*Capra hircus*): Ultrastructural studies. Philipp. J. Sci. 133(1): 33-37.
- Claveria FG, Causapin J, de Guzman MA, Toledo MG and Salibay C, 2005. Parasite biodiversity in *Rattus* spp. caught in wet markets. Southeast Asian J. Trop. Med. Public Health. 36(4):146–148.
- Department of Agriculture (DA), 1999. Department of Agriculture Administrative Order 40, series of 1999. Rules and regulations on the conduct of scientific procedures using animals. Philippine Department of Agriculture. Philippines.
- Dubey JP, Speer CA and Charleston WAG, 1989. Ultrastructural differentiation between *Sarcocystis* of *Sarcocystis hirsuta* and *S. hominis*. Vet. Parasitol. 34(1-2):153–157.
- Dubey JP, Hilali M, Wilpe EV, Calero-Bernal R, Verma SK and Abbas IE, 2015. A review of sarcocystosis in camels and redescription of *Sarcocystis cameli* and *Sarcocystis ippeni* sarcocysts from the one-humped camel (*Camelus dromedarius*). Parasitol. 142(12): 1481-92.
- Gokpinar S, Yildiz K and Gurcan IS, 2014. Prevalence and concentration of *Sarcocystis* spp. microscopic cysts in sheep muscles using percoll gradient centrifugation. ISR J. Vet. Med. 69(1): 16-19.
- Fayer R, Esposito DH and Dubey JP, 2015. Human Infections with *Sarcocystis* Species. Clin. Microbiol. Rev. 28(2): 295-311.
- Hau J, and Van Hoosier JL, 2003. Handbook of Laboratory Animal Science, 2nd Ed: Essential Principles and Practices, Vol. I. CRC Press LLC. Boca Raton, Florida, USA.
- Hu JJ, Meng Y, Guo YM, Liao JY and Song JL, 2012. Completion of the life cycle of *Sarcocystis zuoi*, a parasite from the Norway rat *Rattus norvegicus*. J. Parasitol. 98(3): 550–3.
- Jäkel T, Khoprasert Y, Sorger I, Klimt D, Seehabutr V, Suasaoard K and Hongnark SS, 1997. Sarcosporidiosis in rodents from Thailand. J. Wild. Dis. 33(4): 860-867.
- Jeffery J, Ahmad AF and Abdul-Aziz NM, 2013. *Sarcocystis* spp. and *Pentastomes* in Southeast Asia. pp 177-185. In: Y.A.L. Lim and I. Vythilingam (eds.) Parasites and their vectors. Springer-Verlag Wien, London, UK.



- Lau YL, Chang PY, Tan CT, Fong MF, Mahmud R and Wong KT, 2014. Short Report: *Sarcocystis nesbitti* Infection in Human Skeletal Muscle: Possible Transmission from Snakes. *Am. J. Trop. Med. Hygiene.* 90(2): 361–364.
- Latif B and Muslim A, 2016. Human and animal sarcocystosis in Malaysia: A Review. *Asian Pac. J. Trop. Biomed.* 6(11): 982–988.
- Munday BL and Mason RW, 1980. *Sarcocystis* and related organisms in Australian wildlife: III. *Sarcocystis murinotechis* sp life cycle in rats (*Rattus*, *Pseudomys* and *astocomys* SPP.) and tiger snakes (*Notechis ater*). *J. Wild. Dis.* 16(1):83-87.
- Nichpanit S, Nakai W, Wongsaroj T and Nithikathkul C, 2010. First scale of human *Sarcocystis hominis* in Thailand. *Trends Res. Sci. Tech.* 2(1):1-5.
- Philippine Association for Laboratory Animal Science (PALAS), 2002. Code of Practice for the Care and Use of Laboratory Animals in the Philippines, 2nd Ed. Manila, Philippines.
- Rubio RB and Sumalde AC, 1997. Identification, Biology, Ecology and Management of Rodents. pp. 222–225 In: R.B. Rubio and A.C. Sumalde. Integrated pest management for agroforest farms. Plan International Philippines and UPLB Agroforestry Program. Los Banos, Laguna.
- Salibay CC and Claveria FG, 2005. Serologically confirmed *Toxoplasma gondii* infection in Philippine *Rattus* spp. and its histopathology in *Mus musculus*. *Philipp. J. Sci.* 134(2): 95-104.
- Salibay CC and Luyon HAV, 2008. Distribution of native and non-native rats (*Rattus* spp.) along an elevational gradient in a tropical rainforest of Southern Luzon, Philippines. *Ecotropica.* 14: 129–136.
- University of Pennsylvania UP-IACUC Guideline, 2016. Rodent Euthanasia. Penn Animal Welfare. University of Pennsylvania Institutional Animal Care and Use Committee, USA.

Contribution of Authors

Cabanacan-Salibay CG: Conceived the idea, designed research method, literature review, data analysis and interpretation, manuscript writing
Claveria FG: Conceived the idea, designed research method, data analysis and interpretation, manuscript final reading and approval
Luyon-Tabo HA: Data collection, literature search and review, manuscript final reading and approval
Salibay SPC: Data collection, literature search and review, manuscript final reading and approval
Sumalde AC: Designed research method, data analysis, manuscript final reading and approval
Torres MS: Data collection, analysis and interpretation, statistical analysis, manuscript final reading and approval
Zabal-Dungca J: Designed research methodology, data analysis, manuscript final reading and approval

