



Role of Hybrid Interventions in Management of Critical Lower Limb Ischemia

**Samy R. Zekilah^{1*}, Adel H. Kamhawy¹, Hassan A. Hassan¹,
Mohamed A. El-heniedy¹ and Ahmed M. Ismael¹**

¹Department of Vascular Surgery, Faculty of Medicine, Tanta University, Tanta, Egypt.

Authors' contributions

This work was carried out in collaboration among all authors. Author SRZ designed the study, performed the statistical analysis, wrote the protocol, and wrote the first draft of the manuscript. Authors AHK and HAH managed the analyses of the study and supervised the operative interventions. Author MAEH managed the literature searches. Author AMI managed the linguistic integrity and final arrangement. All authors read and approved the final manuscript.

Article Information

DOI: 10.9734/JAMMR/2020/v32i2430772

Editor(s):

(1) Dr. Sandra Aparecida Marinho, Paraiba State University (Universidade Estadual da Paraiba - UEPB), Brazil.

Reviewers:

(1) Mehmet Işık, Necmettin Erbakan University, Turkey.

(2) Krishna Kumar G., Jawaharlal Institute of Postgraduate Medical Education and Research, India.

Complete Peer review History: <http://www.sdiarticle4.com/review-history/64788>

Original Research Article

Received 25 October 2020

Accepted 30 December 2020

Published 31 December 2020

ABSTRACT

Aims: To evaluate safety and efficacy of the hybrid technique in revascularization of multilevel lower limb arterial occlusive disease in patients with critical lower limb ischemia.

Study Design: A prospective non comparative interventional study.

Place and Duration of Study: It was conducted between February 2017 and June 2019 in the Department of Vascular Surgery, Tanta University hospital.

Methodology: The study included 23 patients were treated with hybrid intervention techniques, and data were collected prospectively. Detailed history was taken and clinical examination was done for every patient along with routine laboratory investigations and radiological work up like duplex scanning with or without CT angiography. All patients were undergone hybrid interventions in an operating room with imaging facilities (mobile c-arm device) where both surgical and endovascular interventions were done simultaneously.

Results: Twenty three patients were treated for unilateral critical lower limb ischemia using single session elective hybrid intervention. The patients age ranged from 46 to 76 (mean 62.6) with 19

*Corresponding author: E-mail: samyzeekilah@yahoo.co.uk;

males. 8 patients (34.8%) presented with ischemic rest pain and the remainder (65.2%) presented with tissue loss (ischemic ulcer or gangrene). most common inflow procedure was femoro-popliteal supragenicular bypass, and the commonest outflow procedure was tibial angioplasty. Technical success was achieved in 22 patients. Mean ABI was improved from 0.49 preoperatively to 0.84 in early post-operative measurements. Out of 23 limbs treated there were 20 limbs saved from amputation (87% limb salvage rate). We had three mortalities from other co-morbidities and four minor complications treated conservatively and resolved.

Conclusion: Hybrid interventions were proved to be reasonable, effective and safe option for treatment of critical lower limb ischemia.

Keywords: Critical limb ischemia; hybrid; endovascular; surgical intervention.

ABBREVIATIONS

Term: Definition for the term

1. INTRODUCTION

Critical lower limb ischemia (CLI) is known as a clinical syndrome of ischemic pain at rest and/or ischemic tissue loss such as non-healing ulcers or gangrene, related to peripheral arterial disease (PAD) of the lower limbs [1].

Its importance is that it is associated with higher risks of limb loss than asymptomatic peripheral arterial disease and intermittent claudication [1,2], it is also associated with excessively high risk for cardiovascular events, including myocardial infarction, and death [3]. Mortality rates as high as 20% within 6 months from diagnosis and exceeding 50% at 5 years have been reported for CLI, [4] Whereas 1-year mortality rates in nonrevascularizable, (so-called no-option CLI patients) range from 10% to 40% [2,5].

Extensive multilevel atherosclerotic disease is common in patients with critical ischemia of the lower extremities. It is frequently associated with multiple medical comorbidities, resulting from disease in distant vascular territories and making these patients high risk for extensive open surgical procedures. The mainstay of treatment for peripheral arterial disease has been arterial bypass surgery, but recent advanced endovascular interventions have challenged surgery as the first-line treatment [6].

Combination of endovascular with open surgical interventions to serve a single particular patient at a single sitting is called the hybrid interventions. These procedures are often performed by a single vascular specialist under a single anesthetic in a single location, with clear patient benefits attributable to that simplified approach and cost savings of almost 50%

compared to staged procedures in different locations [7,8].

Several revascularization permutations exist for the hybrid procedure. In broad terms, they can be separated into surgical bypass or thromboendarterectomy in combination with a catheter-based intervention to improve inflow or outflow. Although individual anatomic and other patient factors will determine the most suitable combination of endovascular and open surgery, so that it is useful to divide multilevel disease into anatomic levels when considering the best approach. We then determine the most appropriate treatment type for each level and, through that delineation, form a concise strategy to complete those procedures during a single operation. This facilitates a complete and durable revascularization while minimizing unnecessary patient movement between procedural settings [8,9].

This study was performed to assess the safety and efficacy of hybrid techniques for lower limb arterial revascularization in the presence of multilevel occlusive disease in patients with critical lower limb ischemia.

2. MATERIALS AND METHODS / METHODOLOGY

This is a prospective non comparative interventional study. It was conducted between February 2017 and June 2019 in the Department of Vascular Surgery, Tanta University hospital, Egypt. The study included 23 patients having PAD category 4 to 6, according to Rutherford classification [10] and multi-level occlusive disease. Patient selection depended upon clinical examination, laboratory investigations, color duplex ultrasound and angiography study. And the **Inclusion criteria** were: PAD category 4 to 6, according to Rutherford classification. Multi-level occlusive disease shown by MSCTA or direct

arteriography where a single modality of treatment seems to be insufficient to solve the problem (mixed TASC A to D in different levels).

Exclusion criteria

The following patients were excluded from the study:

- Patients with known hypersensitivity to contrast agents.
- Patients with active vasculitis.
- Patients with critical cardiac, pulmonary or hepatic conditions.
- Patients with advanced tissue loss (unsalvageable limb).
- Patients with major renal dysfunction (Creatinine >2.4 mg/dl).

2.1 Preprocedural Preparations and Tools

Clopidogrel 300 mg was given 6 to 12 hours orally for cases scheduled to undergo a hybrid intervention in which the surgical part was planned to be a minor intervention with a single arteriotomy and limited dissection, and the endovascular portion was planned for small vessels (to prevent intra operative thrombosis) for example cases undergone common femoral artery (CFA) endarterectomy with superficial femoral artery (SFA) and tibial angioplasty, while cases for whom the surgical part entailed more than one arteriotomy or a bypass especially if a vein harvest was planned, no clopidogrel was given for fear of intraoperative blood loss.

2.2 Technique

2.2.1 Open surgical procedures

CFA endarterectomy: A common type of open surgical procedure done was common femoral endarterectomy (CFEA) (Fig. 1,2). All of them were done by the conventional technique for endarterectomy; The common femoral artery (CFA) and its branches were dissected and clamps applied after full systemic anticoagulation. A longitudinal arteriotomy was done which extended beyond the diseased segment. Using a dissector a plane of endarterectomy was entered in the arterial wall. That plane was extended around the whole circumference of the artery, totally freeing the plaque. The proximal end of the plaque was divided and lifted out of the vessel. However the distal part of the plaque was divided with Pott's scissors exactly at the point at which it remains attached to the arterial wall. If there was any

suggestion that the distal part of the endarterectomized segment was loose, or any evident intimal flap was created two or more tacking sutures were taken. Then inflow and backflow were tested by momentary release of each clamp. All arteriotomies were patched with either a part of the great saphenous vein or a piece of PTFE material.

Other surgical interventions: And this included femoropopliteal bypass using either a vein graft (the great saphenous vein) or a synthetic graft (a 8 mm PTFE graft) for supragenicular bypass and in some cases a part of the vein or synthetic material was used as a patch for the endarterectomized common femoral artery, Femoro-femoral bypass, Iliofemoral thrombectomy (Fogarty catheter thrombectomy), Unilateral aortoiliac endarterectomy, Axillo-femoral bypass and Aorto- bifemoral bypass.

2.2.2 The endovascular portion

The endovascular portion of the procedures was almost uniform and included either supra inguinal intervention (iliac angioplasty with or without stenting) to ensure adequate inflow or infra inguinal catheter based intervention (SFA, popliteal and/or tibials angioplasty with or without stenting) ensuring adequate outflow or both of them (combined inflow and outflow procedures).

2.3 Sheath Placement

Placement of the sheath to initiate the endovascular portion of the procedure was an another important technical point.

For cases where CFA endarterectomy was the only surgical intervention the sheath was put through the endarterectomized segment (before or after patching and establishing the flow) pointing either proximal (for iliac stenting) or distal (for femoropopliteal-tibial angioplasty) or both.

For cases of of femoropopliteal bypass where a vein graft was used as a conduit the sheath was inserted through the proximal anastomosis or a side branch of the vein was kept long enough to admit a sheath where the tip of the sheath was protruded inside the graft thus we were able to image the distal part of the graft, the distal anastomosis and the run off arteries (Fig. 3).

For cases where a synthetic graft was used as a conduit (femoropopliteal supragenicular, cross femoral, aortofemoral or axillofemoral bypass) the sheath was placed either through the surgical

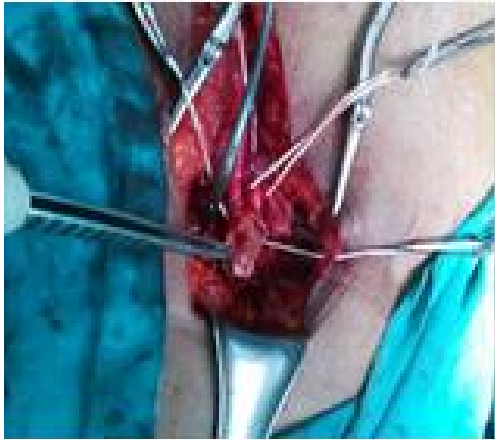


Fig. 1. Open conventional endarterectomy of the common femoral artery

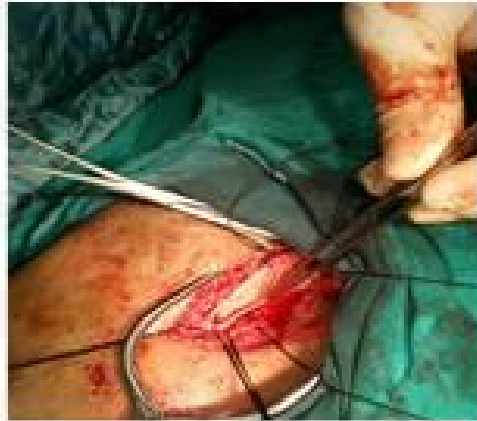

Fig. 2. Common femoral artery after open conventional endarterectomy

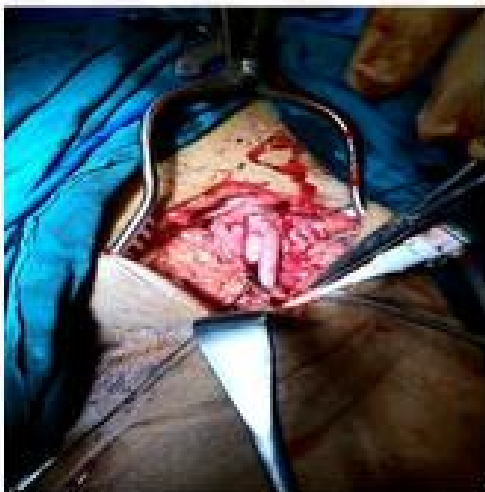

Fig. 3. A sheath in a side branch of the vein graft

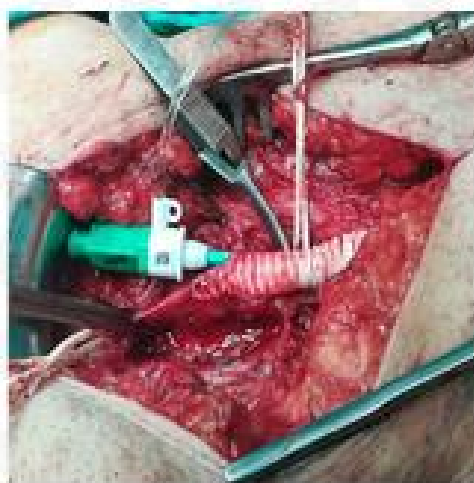

Fig. 4. A sheath inserted through the proximal anastomosis of a synthetic fem-pop 1 graft

anastomosis (Fig. 4) or in the native artery when the surgical segment was remote from the endovascular segment (aortoiliac endarterectomy plus femorodistal catheter based intervention and in cases of iliac stenting prior to fem-pop bypass) or in the native artery distal to the distal anastomosis and after completion of the procedure and removal of the sheath, ligation of the side branch of the vein graft used for sheath entry or tightening and tying of the anastomotic sutures if the sheath was put through an untied anastomosis or closure of the arteriotomy if the sheath was inserted in a native artery.

3. RESULTS

Between february 2017 and June 2019, 23 symptomatic patients underwent 23 elective hybrid interventions for critical unilateral lower limb ischemia. The patient age ranged from 46 to 76 (mean 62.6) with 19 males (82.6%). 11 of them were smokers (47.8%), 12 (52.2%) had history of hypertension, 16 (67%) were diabetics among them there were 11 patients (47.8% of total) with uncontrolled diabetes (HbA1c > 8%) [11], 4 (17.4%) had a history of ischaemic heart disease, Hyper lipidemia_defined as a fasting cholesterol level > 7 mmol/L (270 mg/dL) and a high level of low density lipoprotein

(≥ 160 mg/dL) [12] was found in 7 patients (30.4%).

All patients were presented with unilateral critical lower limb ischemia; 15 (65%) of whom presented with ischaemic ulcers or gangrene and 8 (35%) had rest pain. Ankle –brachial pressure index (ABI) was reliable in 16 patients (69.6%) and it was ranging from 0.35 to 0.60 with a mean ABI of 0.49 and SD \pm 0.0898.

The interventions performed were combinations of inflow or outflow procedures where a combination of surgical and endovascular interventions were done for each particular case (Table 1). And more than one inflow segments were treated in some cases.

Surgical and endovascular portions of the hybrid procedures seemed to be complementary and any jeopardy in one of them resulted in a negative effect on the counter portion for example a dissection occurred in outflow tibial vessels during tibial angioplasty resulted in early thrombosis of a femoropopliteal bypass graft in one of our cases.

Twenty-two out of the 23 patients had follow-up data available (one post operative early mortality), where the follow up period ranged from one month to ten months with a median follow up period of 4 months and a mean of 3.87 months (SD \pm 2.492).

ABI measurement in the early post operative period revealed a considerable improvement in ABI values than the preoperative measurement (Fig. 5) as the range of ABI values pre operatively was from 0.35 to 0.60 with a mean ABI of 0.49 (SD \pm 0.09) while post operative readings ranged from 0.75 to 1 with a mean of 0.844 (SD \pm 0.237) so there was a highly significant statistical difference between measurements before and after the intervention ($p = 0.001$).

As regard the primary patency of the treated segments (clinical and duplex assessment) we found that early patency (in the first post-operative month) was better in segments treated by endovascular means than the surgically treated segments (91% for endovascular portions and 87% for the surgical portions), but it was found that at 10 months the patency of the surgical part was 78% which was superior than the endovascular part that attained a primary patency of only 44% at the tenth post operative month.

For the 15 limbs presented with a clinical picture of critical limb ischemia and tissue loss (ischemic ulcers or gangrene- Rutherford stage 5 and 6), 13 limbs (86.7%) were survived and followed up (as we had 2 early amputations both of them were presented with critical ischemia and tissue loss).

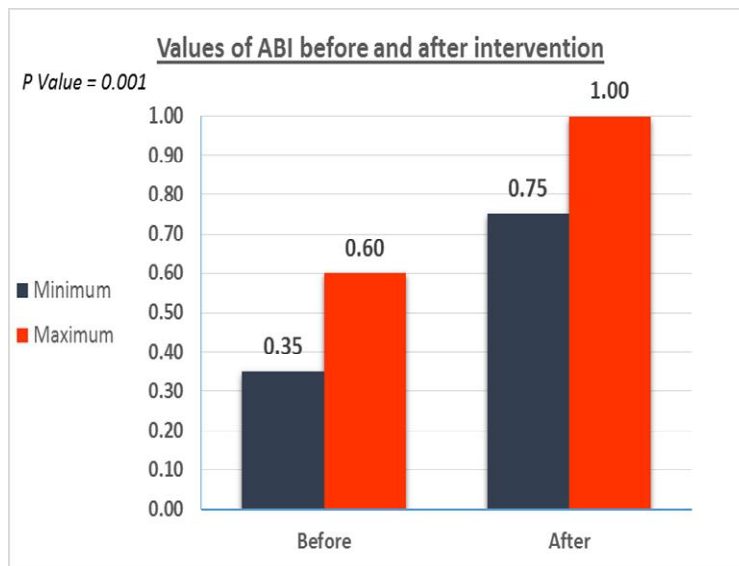


Fig. 5

Table 1. Types of intervention done in different segments

Types of intervention	Technique	Number of cases
Inflow procedures	Aortobifemoral bypass	1
	Aortoiliac endarterectomy	1
	Axillofemoral bypass	1
	Fem-fem bypass	2
	Proximal graft thrombectomy	2
	Iliac stenting	2
	Iliac angioplasty	2
	Iliofemoral thrombectomy	1
	CFA endarterectomy	7
	Fem-pop supragenicular bypass	10
	Popliteal angioplasty	1
Outflow Procedures	CFA endarterectomy	1
	Fem-pop supragenicular bypass	1
	SFA angioplasty	9
	Pop- tibial angioplasty	11
	Popliteal to tibial short bypass	1

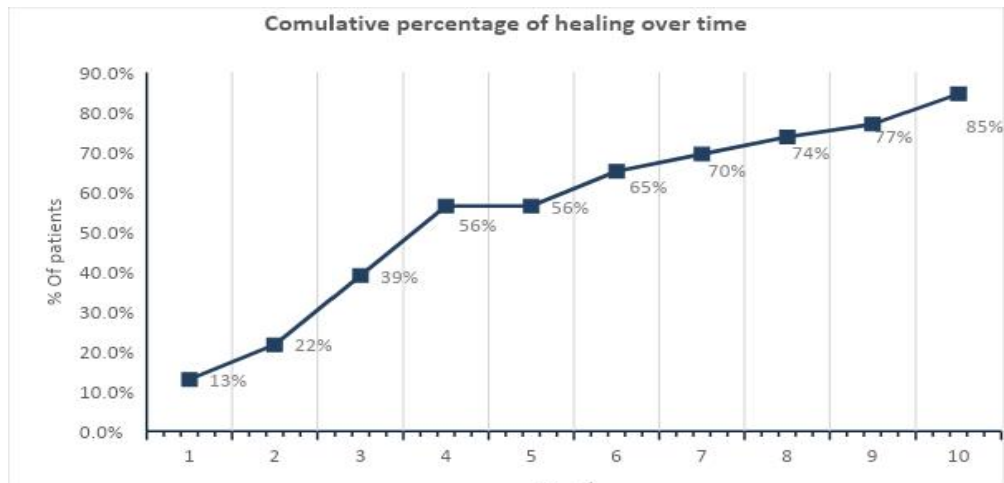


Fig. 6. Cumulative percentage of healing over time (months)

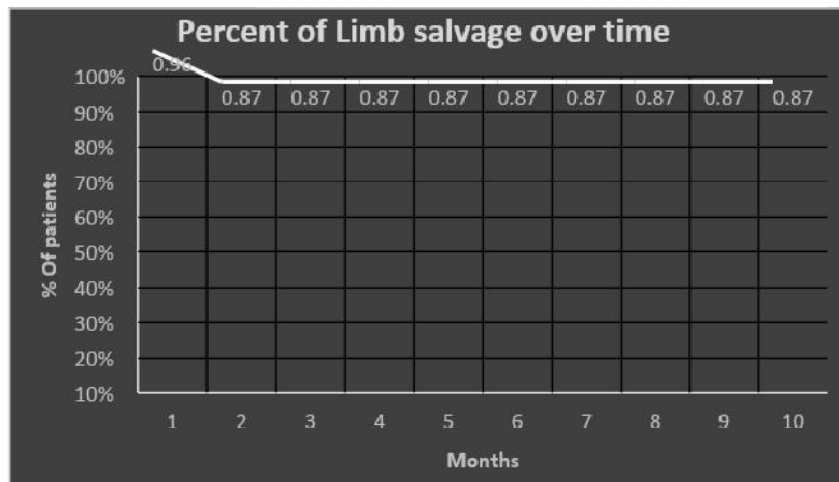


Fig. 7. Kaplan Meier's curve for limb salvage

As assessment of ulcers healing or post debridement wound healing was done by clinical observation and measurement of their dimensions over time, we recorded complete healing of wounds and ulcers in 11 out of 13 limbs (84.6%) at tenth month of follow up (Fig. 6).

Out of 23 limbs treated there were 20 limbs saved from amputation (87% limb salvage rate) as we had one early mortality and two major amputations (Fig. 7).

procedural and early post procedural complications were recorded as the total complication percentage was 17.4% (occurred in 4 patients) where there was two cases of post procedural renal affection with increase in blood urea concentration by 50% of the preoperative values, and were treated successfully and returned to the base line pre operative values and two cases of surgical wound infection treated by antibiotics and did not necessitate wound exploration.

20 patients (87%) were alive at the end of the follow up as there was an early post operative mortality, one patient died at the fourth month of follow up in the critical care unit from acute pneumonia and respiratory failure (she was uncontrolled diabetic) and another patient died at the fifth month from extensive myocardial infarction. No procedure related mortalities (intra-operative or immediate post operative) were recorded.

4. DISCUSSION

This study included a wide spectrum of arterial occlusive disease starting from the aorta down to the tibials which allowed us to go through a wide variety of techniques entailing both surgical and endovascular interventions and to join both modalities in every patient to have the best outcome for that particular patient.

This small sample size compared to other authors is due to the the criteria of selection which include only patients presented with multi-level arterial occlusive disease of the lower limb and suffered from critical limb ischemia) for example Dosluoglu et al. [13] studied 108 patients for evaluation of the outcome of the hybrid intervention for treatment of symptomatic chronic lower limb ischemia of which 63% were claudicants.

Andrew F Seif. et al. [14] published their study of hybrid intervention for 30 critical lower limb ischemia patients where they found that CFA obliteration was the predominant pathology but in this study SFA disease was the most frequent pathology encountered (in 87% of cases) followed by tibial disease (in 47.8% of cases) but surprisingly CFA disease was present only in 9 cases (39%) unlike what was reported by Seif A. F., et al(156) and Thomasa H. et al [15] where they reported a CFA disease necessitating endarterectomy in 100% and 63% of their cohort respectively. This can be explained in part by the nature of our study population where most of them were diabetics (69.5%) with predominant affection of the SFA and tibial vessels and preservation of CFA as it is known for diabetes, and in the other side the criteria of selection, as for example for Seif A. F., et al. [14], CFA disease was an inclusion criteria for their study population.

The most comon types of interventions in the current study were for SFA disease (87%) where 11 femoro-popliteal bypasses and 9 SFA angioplasties were done, followed by tibial interventions (52%) as we have done 11 tibial angioplasties and one popliteal to anterior tibial short bypass, which reflects the heavy atherosclerotic burden confined to the distal arterial tree and this may be attributed to the high incidence of diabetes mellitus among this study cohort. It is noticeable that it was not in agreement with the study done by Dosluoglu et al. [13] as they reported a femoro-popliteal segment intervention in 37% of their patients and intervention for tibial disease in 13% as the incidence of diabetes among their patients was only 34% while 69.5% of our patients were diabetics.

Chang et al. [16] in 2008 published one of the largest series on hybrid intervention as they studied 171 patients for hybrid intervention in chronic lower limb ischemia in the form of iliac stenting and common femoral endarterectomy and they achieved a 80% limb salvage rate but with longer follow up periods, while with Matsagkas et al. [17] in their study in 2011for hybrid revasculariation for 37 patients with critical limb ischemia and sever common femoral artery disease the limb salvage rate was 96% at six months follow up which represents a higher success in limb salvage and this may be attributed to that CFA endarterectomy with its excellent outcome was the principal step in their management strategy.

5. LIMITATION

Limitations to our study include that it is not a multicenter trial, and the heterogeneity of the arterial pathology met in its patients, the short period of follow-up and the absence of control group(s) for comparison. Besides CLI patients are frequently elderly and frail, with short life expectancy and multiple co-morbidities which usually have a negative impact on the outcome as regard the patency, limb salvage and patients' survival

6. CONCLUSION

Hybrid interventions for treatment of critical lower limb ischemia were found to be reasonable, effective and safe options as we use all weapons in our armamentarium in order to serve one patient for providing an online flow to the critically ischemic foot which seems to be the only reasonable solution for those patients.

CONSENT

As per international standard or university standard, patients' written consent has been collected and preserved by the authors.

ETHICAL APPROVAL

It is not applicable.

ACKNOWLEDGEMENTS

Sincere thanks to the patient for sharing their clinical data.

COMPETING INTERESTS

Authors have declared that no competing interests exist.

REFERENCES

1. Hirsch AT, Haskal ZJ, Hertzler NR, et al. ACC/AHA 2005 Practice Guidelines for the management of patients with peripheral arterial disease. *Circulation*. 2006;113:463-654 .
2. Norgren L, Hiatt WR, Dormandy JA, et al. Inter-society consensus for the management of peripheral arterial disease. *Int Angiol*. 2007;26:81-157.
3. Murabito JM, Evans JC, Nieto K, et al. Prevalence and clinical correlates of peripheral arterial disease in the framingham offspring study. *Am Heart J*. 2002;143:961-5.
4. Adam DJ, Beard JD, Cleveland T, et al. Bypass versus angioplasty in severe ischaemia of the leg (BASIL): Multicentre, randomised controlled trial. *Lancet*. 2005; 366:1925-34.
5. Becker F, Robert-Ebadi H, Ricco JB, et al. Chapter I: Definitions, epidemiology, clinical presentation and prognosis of critical lower limb ischemia. *Eur J Vasc Endovasc Surg*. 2011;42(2):S4-S12.
6. Conte MS, Geraghty PJ, Bradbury AW, et al. Suggested objective performance goals and clinical trial design for evaluating catheter-based treatment of critical limb ischemia. *J Vasc Surg*. 2009;50:1462-73.
7. Fernandez N, McEnaney R, Marone LK, et al. Multilevel versus isolated endovascular tibial interventions for critical limb ischemia. *J Vasc Surg*. 2011;54:722-9.
8. Ebaugh JL, Gagnon D, Owens CD, et al. Comparison of costs of staged versus simultaneous lower extremity arterial hybrid procedures. *Am J Surg*. 2008;196:634-40.
9. Menard MT, Farber A. The BEST-CLI trial: a multidisciplinary effort to assess whether surgical or endovascular therapy is better for patients with critical limb ischemia. *Seminars in Vascular Surgery*. 2014;27:82-4.
10. Rutherford RB, Baker JD, Ernst C, et al. Recommended standards for reports dealing with lower extremity ischemia: Revised version. *J Vasc Surg*. 1997;26: 517-38.
11. Suggested standards for reports dealing with lower extremity ischemia. Prepared by the Ad Hoc committee on reporting standards, society for vascular Surgery/North American Chapter, International Society for Cardiovascular Surgery. *J Vasc Surg*. 1986;4:80-94.
12. Todoran TM, Connors G, Engelson BA, et al. Femoral artery percutaneous revascularization for patients with critical limb ischemia: Outcomes compared to patients with claudication over 2.5 years. *Vasc Med*. 2012;17:138-44.
13. Dosluoglu HH, Lall P, Cherr GS, et al. Role of simple and complex hybrid revascularization procedures for symptomatic lower extremity occlusive disease. *J Vasc Surg*. 2010;51:1425-35.
14. Seif A F, Mubarek M A, Elbadawy A H et al. Hybrid management of critical lower limb

- ischemia in Asuit university hospital. Med. J. Cairo Univ. 2018;86:4675-81.
15. Thomasa H , Alya M, Wonga M T. Hybrid Surgical and Radiological Revascularization for Diabetic and Non-Diabetic Lower Limb Ischaemia. J Curr Surg. 2012;2:119-22
16. Chang RW, Goodney PP, Baek JH et al: Long-term results of combined common femoral endarterectomy and iliac stenting/stent grafting for occlusive disease. J Vasc Surg. 2008;48:362–7.
17. Matsagkas M, Kouvelos G, Arnaoutoglou E et al: Hybrid procedures for patients with critical limb ischemia and severe common femoral artery atherosclerosis. Ann Vasc Surg. 2011;25:1063–9.

© 2020 Zekilah et al.; This is an Open Access article distributed under the terms of the Creative Commons Attribution License (<http://creativecommons.org/licenses/by/4.0>), which permits unrestricted use, distribution, and reproduction in any medium, provided the original work is properly cited.

Peer-review history:
The peer review history for this paper can be accessed here:
<http://www.sdiarticle4.com/review-history/64788>