

# Extranodal Rosai-Dorfman Disease of the Nasal Septum: A Case Report

SANTOSH PRASAD KESARI<sup>1</sup>, KARTIKEYA OJHA<sup>2</sup>, PIYUSH<sup>3</sup>, HR SOHAN RAO<sup>4</sup>

## ABSTRACT

Rosai-Dorfman Disease (RDD) is a rare, benign histiocytic proliferative disorder mostly involving the lymph nodes. Extranodal disease can occur in the skin and soft tissue including the mucosal surface, central nervous system, gastrointestinal tract, and breast. Here, a case of a 17-year-old Indo-Asian girl is presented, who came to the Ear Nose Throat (ENT) Outpatient Department (OPD) with a mass in her left nostril for the past two years. A sessile globular mass from the left nasal septum was seen during diagnostic visual endoscopy. A Computerised Tomography (CT) scan of the paranasal sinus revealed a rather large right maxillary sinus with a soft tissue density lesion filling it and obliterating the osteomeatal complex, while blood tests revealed an increased eosinophilic count. The nasal tumour was removed, and its histological analysis revealed characteristics of RDD. This is typically sporadic histiocytosis with emperipolesis in the cells. Clinically, the condition is benign, and all that is required is conservative therapy and periodic monitoring of its progression. Surgical excision is rarely advised until the disease has grown to an unmanageable size and is causing respiratory impairment or a cosmetic deformity. Currently, therapy revolves around surgical and immunosuppressive treatments, but the optimal diagnostic and therapeutic management of RDD remains to be defined.

**Keywords:** Deviated nasal septum, Histiocytosis, Inferior turbinate hypertrophy, Septal mass

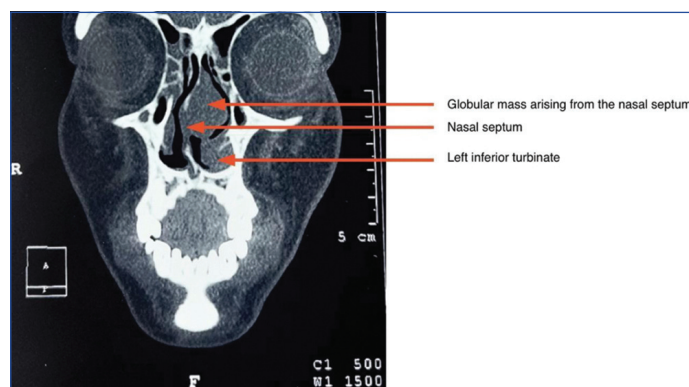
## CASE REPORT

An 17-year-old Indo-Asian girl reported to the ENT OPD with complaints of Nasal mass in the left nostril for the past two years. The swelling was gradually progressive in size and painful to the touch; it was associated with a running nose and frequent sneezing. There was also a history of snoring and recurrent allergy to dust in the past two years, which were being treated with topical nasal drops and antihistaminics. The allergies were exacerbated during the winter season. The swelling did not bleed on the touch. There was no history of discharge.

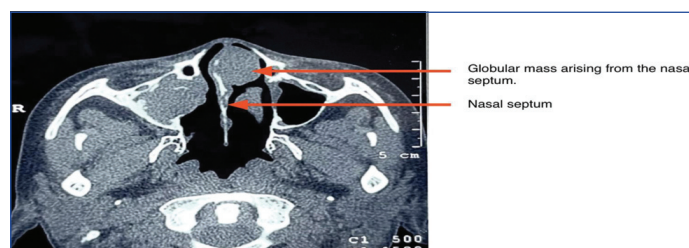A physical examination of the nose revealed a globular mass arising from the left-side of the nasal septum with the deviated nasal septum towards the right-side, and a nasal spur on the right-side. A sessile globular mass from the left nasal septum was visualised on diagnostic nasal endoscopy. Laboratory investigations revealed an elevated Eosinophilic count ( $>40 \times 10^3/uL$ ).

A CT scan of the paranasal sinus revealed that the left maxillary sinus was relatively enlarged in size, with a soft tissue density lesion filling it and obliterating the osteomeatal complex. The periosteal reaction was seen circumferentially along the inner margin of the right maxillary sinus. A soft tissue density polypoidal lesion was seen along the left lateral margin of the nasal septum, measuring 18×22×27 mm in Craniocaudal X Transverse X Anteroposterior dimensions. Mild mucosal thickening was seen in the right frontal, bilateral ethmoid, bilateral sphenoid, and left maxillary sinuses [Table/Fig-1,2].

The nasal septum deviated to the right-side with hypertrophy of the left inferior turbinate. The left osteomeatal complex was normal. Bilateral orbital margins were intact, and the overlying soft tissue was normal. All preoperative investigations, including complete blood count (excluding eosinophilic count), serum electrolytes, viral markers including Human Immunodeficiency Virus (HIV), Liver Function Tests (LFTs), Kidney Function Tests (KFTs), Prothrombin Time (PT), Activated Partial Thromboplastin Time (APTT), Chest X-ray were within normal limits. Under general anaesthesia, the growth was surgically removed, and the left inferior turbinoplasty was performed using a debrider. The pre-operative view of the left nostril showing the smooth swelling arising from the nasal septum on the left-side can be seen in [Table/Fig-3,4]; The intraoperative view of the septal mass removed in toto can be seen in [Table/Fig-5,6]; Postoperative view of the raw area of



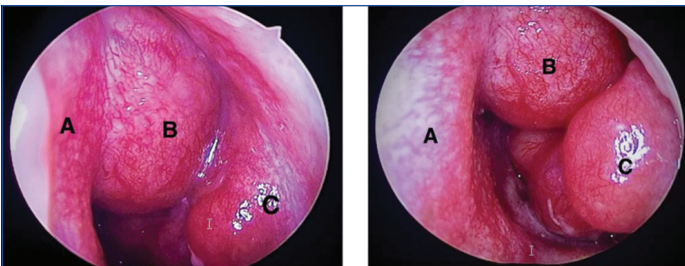
**[Table/Fig-1]:** On the coronal section of CT face, nasal septum is seen to be deviated to the right-side. A globular mass can be seen arising from the left-side of the nasal septum with hypertrophy of the left inferior turbinate hypertrophy. (red arrows)



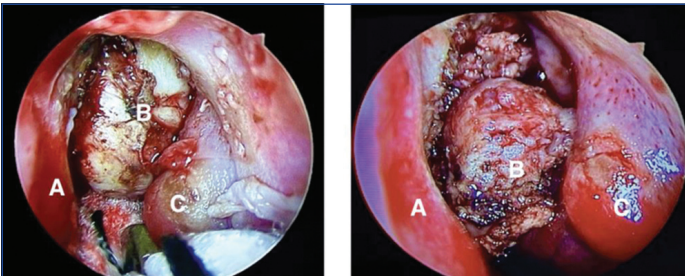
**[Table/Fig-2]:** On axial section of CT face nasal septum is seen to be deviated to the right-side. A globular mass can be seen arising from the left-side of the nasal septum. Mucosal thickening can be appreciated in the right maxillary sinus. (red arrows)

nasal septum after removal of septal mass can be seen in [Table/Fig-7,8]; With 'A' being the Nasal Septum, 'B' being the Inferior Turbinate, and 'C' being the Globular Mass in each figure.

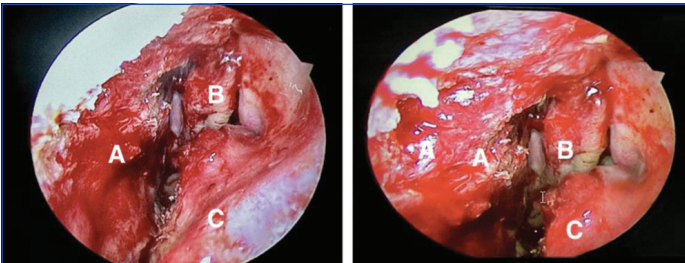
The mass was excised as a whole and sent for histopathological examination [Table/Fig-9]. It revealed fragmented tissue bits focally lined by respiratory epithelium showing mild reactive atypia. Stroma showed dense and diffused chronic inflammatory cells with sheets of small non cleaved lymphocytes, many plasma cells with rare cells showing binucleation, scattered histiocytes and occasional histiocytes showing emperipolesis of intact lymphocytes and rare occasional eosinophils. In places, stroma showed oedema. No



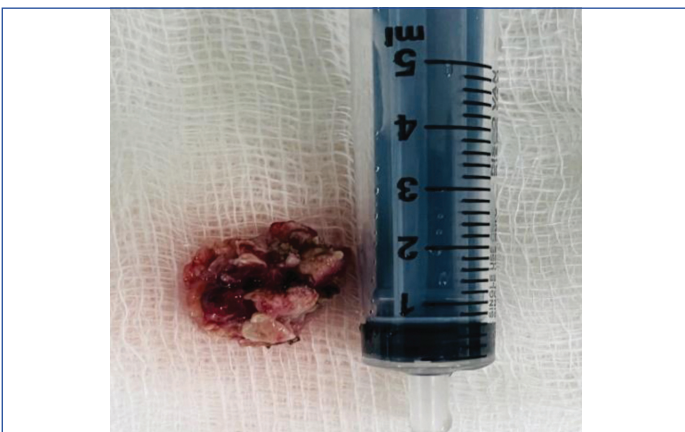**[Table/Fig-3,4]:** Preoperative view of the left nostril showing the smooth swelling arising from the nasal septum on the left side. (Images from left to right)  
A: Nasal Septum; B: Globular Mass; C: Inferior Turbinate



**[Table/Fig-5,6]:** Intraoperative view of septal mass removed in toto. (Images from left to right)  
A: Nasal Septum; B: Globular Mass; C: Inferior Turbinate



**[Table/Fig-7,8]:** Postoperative view of raw area of nasal septum after removal of septal mass. (Images from left to right)  
A: Raw area of Nasal Septum; B: Middle Turbinate; C: Inferior Turbinate

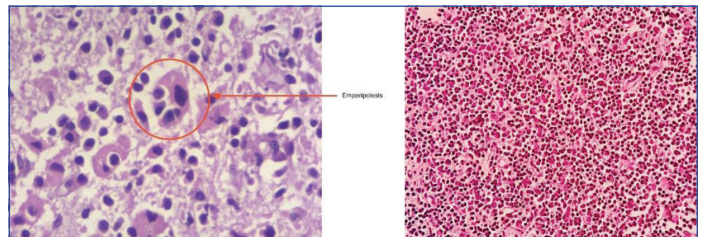


**[Table/Fig-9]:** Excised mass of size 1.8x1.5 cm.

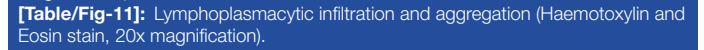
evidence of atypical cells and bizarre cells, atypical mitosis, granuloma, or fungal elements in the section. The finding was consistent with RDD [Table/Fig-10-13]. After two weeks of the surgery, the patient was followed-up and maintained optimum health.

## DISCUSSION

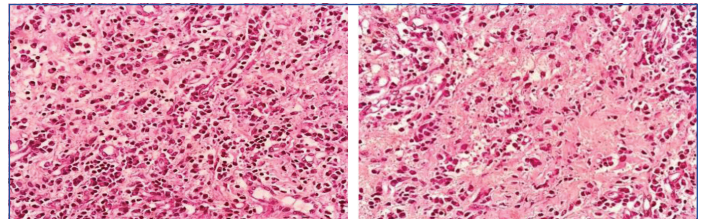
The RDD is a rare condition with a prevalence of 1:200 000 and an estimated 100 new cases yearly in the United States [1]. RDD is rare in India, only about a dozen cases have been reported, mostly in children and very few in adults [2]. It is a malignant, non Langerhans cell histiocytosis of unknown cause characterised by an accumulation of activated histiocytes within the affected tissue. RDD is more prevalent in men and people of African origin, with the cutaneous variant being more prevalent in Asian women [3]. Constitutional symptoms and laboratory signs of inflammation may



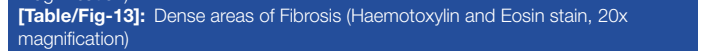
**[Table/Fig-10]:** Cells showing emperipolesis (Haematoxylin and Eosin stain, 40x magnification).



**[Table/Fig-11]:** Lymphoplasmacytic infiltration and aggregation (Haematoxylin and Eosin stain, 20x magnification).



**[Table/Fig-12]:** Sheets of lymphocytes (Haematoxylin and Eosin stain, 20x magnification).



**[Table/Fig-13]:** Dense areas of Fibrosis (Haematoxylin and Eosin stain, 20x magnification)

exist but are not mandatory [4]. Although, it is widely documented in lymph nodes and other organs, it is frequently not recognised in soft tissues. RDD exists in two main varieties: solely Cutaneous RDD (CRDD) [5] and one that affects the lymph nodes and, in some cases, extranodal organs [6]. The classic presentation of RDD consists of bilateral, massive, and painless cervical lymphadenopathy with or without intermittent fevers, night sweats, and weight loss [7].

The extranodal illness, which most frequently affects the skin, nasal cavity, and orbit, develops in about 43% of individuals [8]. The testes, spleen, and salivary glands may be affected [9,10]. Although, highly unusual, cutaneous illness without lymphadenopathy has been seen [11,12].

Nasal obstruction and epistaxis are two frequent symptoms brought on by the extra-nodal invasion of the sinuses and nasal cavity. Rarely is the nasal septum invaded. Leukocytosis and an accelerated Erythrocyte Sedimentation Rate (ESR) typically describe laboratory findings. Due to the lack of pathognomonic clinical characteristics, nasal RDD is frequently misdiagnosed in clinical practice [13]. The absence of typical RDD symptoms at the presentation made it difficult to diagnose our case. Despite laboratory results indicating eosinophilia, her body temperature, ESR, and other organ involvement were all within normal range. Raje P and Vyas P reported a case in India of a 58-year-old female patient with extra-nodal RDD of nasal septal mucosa without lymphadenopathy who had presented with complaints of difficulty in breathing and frequent episodes of epistaxis for three months [2].

Wang J et al., presented a case of a 55-year-old woman who presented to our hospital with nasal dorsum collapse while wearing her glasses with occasional epistaxis. Wang J et al., reported a similar observation in which the patient had no clinical signs of RDD and the laboratory results only revealed leukocytosis [13]. A case by Akyigit A et al., reports a similar finding: 15-year-old male patient: the mass completely filled the left nasal meatus and caused difficulty in breathing through both nasal meatus while deviating the septum to the right [14]. The present case is of an Asian Indian Girl with RDD with nasal obstruction without any lymphadenopathy, making it very rare.

The traits of RDD in bone and soft tissue are ambiguous and frequently deceptive. Erdheim-Chester disease, lymphoma, plasma cell myeloma, and metastatic disease are among the differential diagnosis [15]. Several differential diagnoses (nasal polyp, inferior turbinate hypertrophy, and nasal tumours) were ruled out in the present instance. As the mass is arising from the septum and it is firm too hard in consistency, the possibility of the nasal polyp was ruled out clinically. As the mass

was attached to the septum and on probe test there was no lateral attachment, and inferior turbinate hypertrophy was ruled out. The mass did not bleed on touch which is contrary to the findings reported by Raje P and Vyas P and Wang J et al., [2,13] and there was no bone erosion as noted on the CT-PNS scan which was contrary to the case reported by Wang J et al., the possibility of nasal tumours was ruled out [13].

RDD is characterised histologically by an attenuated dermal infiltration of pale histiocytes and lymphoplasmic cells of varying sizes [16]. These histiocytes have single prominent nucleoli and round or oval vesicular nuclei with well-defined, delicate nuclear membranes. Neutrophils and eosinophils are occasionally seen. RDD is incredibly uncommon, the lesions are clinically varied, and it can mimic various conditions, including other histiocytoses, lymphomas, sarcoidosis, viral diseases, and other histiocytoses [17]. The cytoplasm of the histiocytes frequently contains phagocytised lymphocytes and plasma cells, a finding known as emperipolesis in the histology of RDD [18]. Since, extra-nodal RDD can be imperceptible and extra-nodal lesions typically have greater fibrosis, fewer RDD histiocytes, and less emperipolesis, emperipolesis is not necessary for the diagnosis [19]. Histological analysis of the mass removed in this case revealed cells with emperipolesis combined with thick fibrotic regions, lymphoplasmacytic infiltration, and aggregation, supporting RDD as the origin of the mass which is similar to findings of the cases reported by Raje P and Vyas P; Akyigit A et al., and Wang J et al., [2,13,14]. Since RDD's course typically self-limits, close observation is the advised management strategy. Surgical excision is the most effective course of action when management is necessary, such as in lesions that are physically compressing surrounding tissue or in lesions that are affecting internal organs. Oral steroids should be started in cases of fever  $>38^{\circ}\text{C}$  without a known illness and unexpected lymph node enlargement [17]. Although, anecdotal reports of the use of corticosteroids, thalidomide, radiation, and alkylating drugs exist, their efficacy has not been established [20]. Various treatment approaches have been suggested for individuals based on prior case reports, including cryotherapy, surgical excision, irradiation, oral corticosteroids, dapsone, thalidomide, and isotretinoin [21,22].

In the case reported by Raje P and Vyas P the mass was endoscopically excised [2], in the case presented by Akyigit A et al., the mass was excised surgically [14], and in the case presented by Wang J et al., most of the diseased tissue was excised for pathological examination [13]. However, No further treatment was performed, for the patient's personal reasons. Moreover, in the second postoperative year, the tumour grew back which was then surgically excised following which there was no recurrence. Similarly, the tumour in the patient's case necessitated removal because it was blocking the patient's airway and causing the nasal septum to deviate to the opposite side.

## CONCLUSION(S)

The RDD is a rare, benign proliferative disease mainly affecting the lymphatic tissues, however, the disease may manifest in extranodal sites, including the skin and the mucosal site. The present case

discusses an Indo-asian patient with RDD of the nose without lymphadenopathy. Eventhough, most cases resolve on their own surgical excision is recommended for a larger tumour involving the airway which causes airway compromise just like in the present case. The appropriate management of RDD must be established by well-designed studies to draw firm conclusions.

## REFERENCES

- [1] Mahzoni P, Zavareh MH, Bagheri M, Hani N, Moqtader B. Intracranial Rosai-Dorfman disease. *Journal of Research in Medical Sciences: The Official Journal of Isfahan University of Medical Sciences*. 2012;17(3):304.
- [2] Raje P, Vyas P. Extra nodal Rosai Dorfman disease of nasal septal mucosa without lymphadenopathy. *Journal of Pathology of Nepal*. 2016;6(11):968-70.
- [3] Kutlubay Z, Bairamov O, Sevim A, Demirkesen C, Mat MC. Rosai-Dorfman disease: a case report with nodal and cutaneous involvement and review of the literature. *The American Journal of Dermatopathology*. 2014;36(4):353-57.
- [4] Mosheimer BA, Oppl B, Zandieh S, Fillitz M, Keil F, Klaushofer K, et al. Bone involvement in Rosai-Dorfman disease (RDD): a case report and systematic literature review. *Current Rheumatology Reports*. 2017;19(5):01-05.
- [5] Thawarani H, Sanchez RL, Rosai J, Dorfman RF. The cutaneous manifestations of sinus histiocytosis with massive lymphadenopathy. *Archives of Dermatology*. 1978;114(2):191-97.
- [6] Rosai J, Dorfman RF. Sinus histiocytosis with massive lymphadenopathy: a pseudolymphomatous benign disorder. Analysis of 34 cases. *Cancer*. 1972;30(5):1174-88.
- [7] Al-Khateeb TH. Cutaneous Rosai-Dorfman disease of the face: A comprehensive literature review and case report [J]. *J Oral Maxillofac Surg*. 2016;74(3):528-40.
- [8] Vaiselbuh SR, Bryceson YT, Allen CE, Whitlock JA, Abila O. Updates on histiocytic disorders. *Pediatr Blood Cancer*. 2014;61:1329-35.
- [9] Kismet E, Koseoglu V, Atay AA, Deveci S, Demirkaya E, Tuncer K. Sinus histiocytosis with massive lymphadenopathy in three brothers. *Pediatr Int*. 2005;47:473-76.
- [10] Elbaz Younes I, Sokol L, Zhang L. Rosai-dorfman disease between proliferation and neoplasia. *Cancers*. 2022;14(21):5271.
- [11] Wang KH, Chen WY, Liu HN, Huang CC, Lee WR, Hu CH. Cutaneous Rosai-Dorfman disease: clinicopathological profiles, spectrum and evolution of 21 lesions in six patients. *British Journal of Dermatology*. 2006;154(2):277-86.
- [12] Brenn T, Calonje E, Granter SR, Leonard N, Grayson W, Fletcher CD, et al. Cutaneous Rosai-Dorfman disease is a distinct clinical entity. *The American Journal of Dermatopathology*. 2002;24(5):385-91.
- [13] Wang J, Wang Y, Li G, Wang C, Yu G, Sun Y. Rosai-Dorfman disease originating from nasal septal mucosa and presenting with nasal dorsum collapse: A case report with literature review. *Ear, Nose & Throat Journal*. 2022:01455613221079500.
- [14] Akyigit A, Akyol H, Sakallioğlu O, Polat C, Keles E, Alatas O. Rosai-Dorfman disease originating from nasal septal mucosa. *Case Reports in Otolaryngology*. 2015;2015:232898.
- [15] Garcia RA, DiCarlo EF. Rosai-Dorfman Disease of bone and soft tissue. *Archives of Pathology & Laboratory Medicine*. 2022;146(1):40-46.
- [16] Bruce-Brand C, Schneider JW, Schubert P. Rosai-Dorfman disease: an overview. *Journal of Clinical Pathology*. 2020;73(11):697-705.
- [17] Hinojosa T, Ramos E, Lewis DJ, del Angel L, Vangipuram R, Peranteau AJ, et al. Cutaneous Rosai-Dorfman disease: A separate clinical entity. *Journal of Dermatology & Dermatologic Surgery*. 2017;21(2):107-09.
- [18] Haroche J, Cohen-Aubart F, Rollins BJ, Donadieu J, Charlotte F, Idhah A, et al. Histiocytoses: emerging neoplasia behind inflammation. *Lancet Oncol*. 2017;18(2):e113-25.
- [19] Abila O, Jacobsen E, Picarsic J, Krenova Z, Jaffe R, Emile J-F, et al. Consensus recommendations for the diagnosis and clinical management of Rosai-Dorfman-Destombes disease[J]. *Blood*. 2018;131(26):2877-90.
- [20] Pulsoni A, Anghel G, Faluccci P, Matera R, Pescarmona E, Ribersani M, et al. Treatment of sinus histiocytosis with massive lymphadenopathy (Rosai-Dorfman disease): report of a case and literature review. *American Journal of Hematology*. 2002;69(1):67-71.
- [21] Sun NZ, Galvin J, Cooper KD. Cutaneous Rosai-Dorfman disease was successfully treated with low-dose methotrexate. *JAMA Dermatology*. 2014;150(7):787-88.
- [22] Karami R, Ghieh F, Baroud J, Sittah GA. Rosai-Dorfman Disease: cutaneous and parotid involvement. *Annals of Plastic Surgery*. 2019;82(6):639-41.

### PARTICULARS OF CONTRIBUTORS:

1. Associate Professor, Department of Ear, Nose and Throat, Sikkim Manipal University, Gangtok, Sikkim, India.
2. Intern, Sikkim Manipal University, Gangtok, Sikkim, India.
3. Postgraduate Trainee, Department of Ear, Nose and Throat, Sikkim Manipal University, Gangtok, Sikkim, India.
4. Senior Resident, Department of Pathology, Sikkim Manipal University, Gangtok, Sikkim, India.

### NAME, ADDRESS, E-MAIL ID OF THE CORRESPONDING AUTHOR:

Santosh Prasad Kesari,  
Associate Professor, Department of Ear, Nose and Throat, Central Referral Hospital, Sikkim Manipal Institute of Medical Sciences, 5th Mile, Tadong, Gangtok, Sikkim, India.  
E-mail: santosh4uma@yahoo.co.in

### AUTHOR DECLARATION:

- Financial or Other Competing Interests: None
- Was informed consent obtained from the subjects involved in the study? Yes
- For any images presented appropriate consent has been obtained from the subjects. Yes

### PLAGIARISM CHECKING METHODS: [Jain H et al.]

- Plagiarism X-checker: Dec 07, 2022
- Manual Googling: Jan 12, 2023
- iThenticate Software: Feb 07, 2023 (7%)

### ETYMOLOGY: Author Origin

Date of Submission: **Nov 23, 2022**

Date of Peer Review: **Jan 11, 2023**

Date of Acceptance: **Feb 22, 2023**

Date of Publishing: **Apr 01, 2023**