



# **Role of Suprachoroidal Anti-VEGF Injections in Recalcitrant Serous Pigment Epithelium Detachment**

**Ditsha Datta<sup>a++\*</sup>, Perwez Khan<sup>a#</sup>,  
Lubna Khan<sup>b†</sup> and Ankita Singh<sup>a,c‡</sup>**

<sup>a</sup> Department of Ophthalmology, GSVM Medical College, Kanpur, India.

<sup>b</sup> Department of Pathology, GSVM Medical College, Kanpur, India.

<sup>c</sup> Department of Ophthalmology, RML Institute of Medical Sciences, India.

## **Authors' contributions**

*This work was carried out in collaboration among all authors. All authors read and approved the final manuscript.*

## **Article Information**

DOI: 10.9734/OR/2023/v18i3385

## **Open Peer Review History:**

This journal follows the Advanced Open Peer Review policy. Identity of the Reviewers, Editor(s) and additional Reviewers, peer review comments, different versions of the manuscript, comments of the editors, etc are available here:  
<https://www.sdiarticle5.com/review-history/99193>

**Original Research Article**

**Received: 22/02/2023**  
**Accepted: 25/04/2023**  
**Published: 02/05/2023**

## **ABSTRACT**

**Purpose:** Retinal pigment epithelial detachments (PEDs) are characterized by a separation between the RPE and the innermost aspect of Bruch's membrane. Many chorioretinal diseases can lead to pigment epithelial detachment of which the most common is age-related macular degeneration; but a significant number of PEDs are idiopathic in etiology. PEDs can be classified as drusenoid, serous, vascularized, or fibrovascular type. Currently, serous PED has not shown much response to treatment, so no specific treatment guidelines are established. Whereas vascularized PEDs, have several treatment options such as intravitreal anti-Vascular endothelial growth factor (VEGF) therapy, laser photocoagulation,

<sup>++</sup> Senior Resident;

<sup>#</sup> Professor and Head;

<sup>†</sup> Professor and Blood Bank Incharge;

<sup>‡</sup> Assistant Professor;

\*Corresponding author: E-mail: medicoditsha@rediffmail.com;

photodynamic therapy (PDT) and intravitreal steroids. Hence, the need of the hour is to formulate a treatment strategy for serous PED.

**Methods:** We report an original study of thirty patients who were diagnosed with serous pigment epithelial detachment on Spectral-domain optical coherence tomography and fundus fluorescence angiography. All the patients presented to our outpatient department with the chief complaint of diminution of vision, central/paracentralscotoma and metamorphopsia. All of them underwent treatment with suprachoroidal anti-VEGF (bevacizumab). The patients were followed 8 weeks.

**Results:** BCVA and Amsler grid assessment was recorded on the 3rd day, 1st week, 2nd week, 4th week, 6th week, and 8th week. Post-injection SD-OCT macular scan was performed on the 6<sup>th</sup> week. Functional improvement (BCVA) was reported by all patients. All the patients had reduced size and height of PED in SD-OCT.

**Conclusion:** Thus, our result indicates that suprachoroidal bevacizumab is an efficacious treatment for serous PED. It can be hypothesized that as degenerative changes in bruch membrane due to metabolite deposit plays a key role in development of PED; injecting the anti VEGF drug in the suprachoroida space adjacent to the choroid has a superior effect.

*Keywords: serous PED; suprachoroidal; anti VEGF.*

## 1. INTRODUCTION

Pigment epithelium detachment (PED) is the separation between the monolayer retinal pigment epithelium and underlying Bruch's membrane [1]. The prevalence is highest in patients with neovascular Age-Related Macular Degeneration (nAMD). Other ocular conditions like Idiopathic Central Serous Chorioretinopathy (CSCR), polypoidal choroidal vasculopathy (PCV) and Vogt Koyanagi Harada syndrome (VKH) may present along with PEDs [2]. PEDs have also been reported in some systemic conditions like infections, autoimmunity, lymphoma, leukemia and renal disorders [3].

The exact pathology of PED is unknown and several contributing mechanisms have been proposed for their development. The most acceptable theory states that due to the progressive deposition of metabolic waste products like lipids, cholesterol esters, triglycerides and fatty acids in Bruch's membranes, normal retino-choroidal flow is hampered and fluid gets accumulated beneath the RPE leading to the structural splitting. Choroidal hyperpermeability also plays a role in serous PED pathogenesis. Based on their contents they are classified into serous, drusenoid, and hemorrhagic, although, simultaneously co-existence of more than one type is not uncommon [4].

Clinically, a patient of PED generally presents with sub-acute blurring of vision, metamorphopsia, or scotoma in the central visual field. The diagnosis of the PED is made on fundus examination combined with multimodal imaging techniques [4].

The treatment of PED has always remained a challenge. Strategies like Verteporfin photodynamic therapy (PDT), laser photocoagulation, and intravitreal anti-vascular endothelial growth factors (VEGFs) have been used for managing vascularized PED [5]. However, these strategies have otherwise proven ineffective for isolated serous PED.

For the management of such recalcitrant cases various novel techniques have been tried and one of them is injecting anti-VEGFs into suprachoroidal space (SCS). The SCS is the potential space between the sclera and choroid [6]. The recent advancements in imaging techniques have made it's in vivo examination possible via Optical coherence tomography (OCT) [7]. Various studies have demonstrated that drugs injected into the SCS rapidly diffuse into the vitreous cavity, bypassing the risks of intraocular penetration [8]. Hence, the rationale of injecting anti-VEGF into SCS, targeting the hyperpermeable choroid in patients of recalcitrant serous PED appears promising.

Therefore, the authors report a study of thirty patients for the management of recalcitrant PED by injecting anti-VEGF into the supra choroidal space. As already stated degenerative changes in bruchs membrane due to metabolite deposition with choroidal hyperpermeability is a key factor in development of PED. By injecting the anti VEGF in the suprachoroidal space adjacent to the choroid, a superior and prolonged rejuvenating effect on bruchs membrane and reduced choroidal permeability is expected. There were 22 male and 8 female patients in the age group of 27 to 50 years.

## 2. METHODS

All the patients presented to us with the complaint of blurred vision in the affected eye for approximately past a year which was subacute in onset, nonprogressive. Many patients also complained of associated scotoma in the central field.

All patients had taken treatment in the form of one or two doses of intravitreal anti-VEGF ranibizumab at some other center, but no improvement was noted in due course of time. On the Amsler grid, metamorphopsia was noted. Dilated fundus examination revealed a well-defined dome-shaped elevation of the retina at the macula. Neither hemorrhages nor drusen were associated with it. The diagnosis was confirmed on spectral domain-OCT a small zone of RPE elevation with some subretinal fluid at the macula was appreciated which confirmed the diagnosis of serous PED. Keeping in mind the previous treatment history of the patient, the diagnosis of recalcitrant serous PED was made. The average height of serous PED measured with inbuilt scale of OCT software was  $676.8 \pm 156.4$  microns.

Patients were subjected to treatment with two doses of 0.1 ml of suprachoroidal anti-VEGF (bevacizumab) at the monthly interval through an indigenously designed device which penetrates the sclera to reach the suprachoroidal space but not deeper (device has been fashioned out of 26 G hypodermic needle with 20G steel sleeves fitting snugly over the hypodermic needle ensuring effective needle length of 500-1000 microns for controlled and accurate drug delivery). The needles were connected to tuberculin syringe for injection. Patent for this device has already been applied. The suprachoroidal space is highly vascular; thus a smaller molecule like ranibizumab (molecular weight 48 kDa) if injected carries the risk of being washed away. Bevacizumab was chosen because it has a higher molecular weight (149 kDa) being a complete antibody so fewer chances of losing it in the circulation. Patients were followed up on the 3rd day, 7th day, 2nd week, 4th week, 6th week, and 8th week from the first injection.

Intraocular pressure (IOP) was measured immediately after injection showing a transient rise in a number of subjects.

## 3. RESULTS

The collected data was analysed by Statistical Package for Social Science (IBM Corp. released 2011, IBM SPSS Statistics for Windows, Version 20.0. Armonk, NY: IBM Corp). Data was compiled and suitable statistical tests for analysis were done according to the type of data obtained for each parameter.

All patients showed improvement in BCVA from the 7<sup>th</sup> day after the first injection. Patients were provided with Amsler grid to monitor metamorphopsia and scotoma on daily basis. All patients started to notice improvement in the above parameters from around 2 weeks post injection.

On fundus examination reduction in the size of PED was noted from the 2<sup>nd</sup>-week post-injection, with only some pigmentary disturbance in the subfoveal area. This reduction in size was assessed with inbuilt measuring scales of the fundus camera software.

OCT was repeated for all the patients at 6<sup>th</sup> week of follow up, which revealed decrease in height of PED (mean PED height  $108.6 \pm 52.4$  microns); although some disorganization of inner retinal layers was noticeable nasal to fovea. PED size was assessed with inbuilt measuring scales of the OCT machine. This reduction in mean height of serous PED from  $676.8 \pm 156.4$  microns pre injection to  $108.6 \pm 52.4$  microns post injection is statistically significant ( $p$  value  $< 0.05$ ). On fundus examination also PED was reduced in height with some pigmentary disturbance.

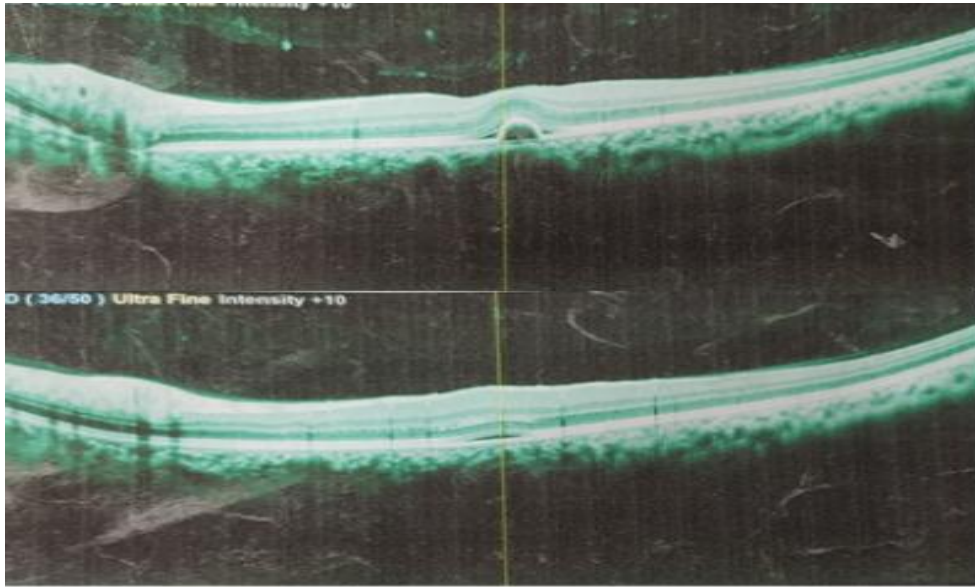
BCVA of patients recorded on 3<sup>rd</sup> day, 7<sup>th</sup> day, 2<sup>nd</sup> week, 4<sup>th</sup> week, 6<sup>th</sup> week and 8<sup>th</sup> week from first injection showed improvement from the 7<sup>th</sup> day after the first injection. (Tables 1 and 2). Mean logMAR BCVA reduced from 0.604 pre injection to a final logMAR BCVA of 0.146667 at 8 weeks post injection which is statistically significant ( $p$  value  $< 0.05$ ). Further improvement in vision occurred on subsequent monthly follow up.

OCT was repeated for all the patients at 6<sup>th</sup> week of follow up, which revealed decrease in height and size of PED (Figs. 1, 2, 3, 4).


The rise in IOP noted immediately post injection was transient in nature and responded well to 500 mg stat dose of oral acetazolamide.

Patients also subjectively reported that the suprachoroidal injection was associated with more pain as compared to the intravitreal injections they received in past. No floaters were experienced which is a common complaint in the intravitreal injections. RPE tears which are

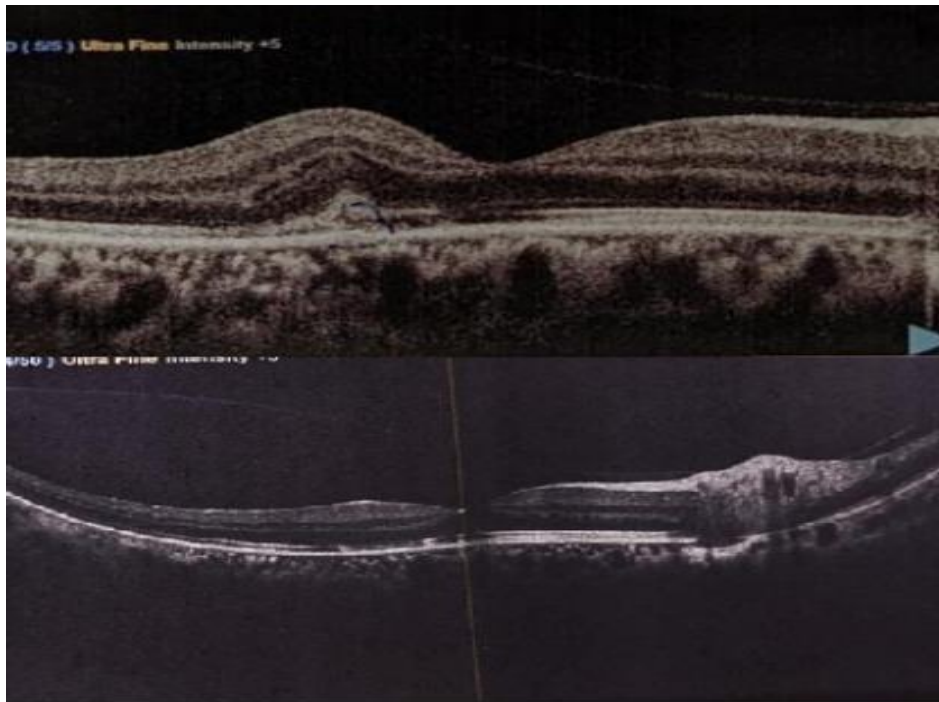
dreadful complications in PED patients post intravitreal anti-VEGF were not reported in any of the cases post suprachoroidal injections. None of the patients showed any sign of ocular infection, raised IOP, vitritis, vitreous hemorrhage or cataract.



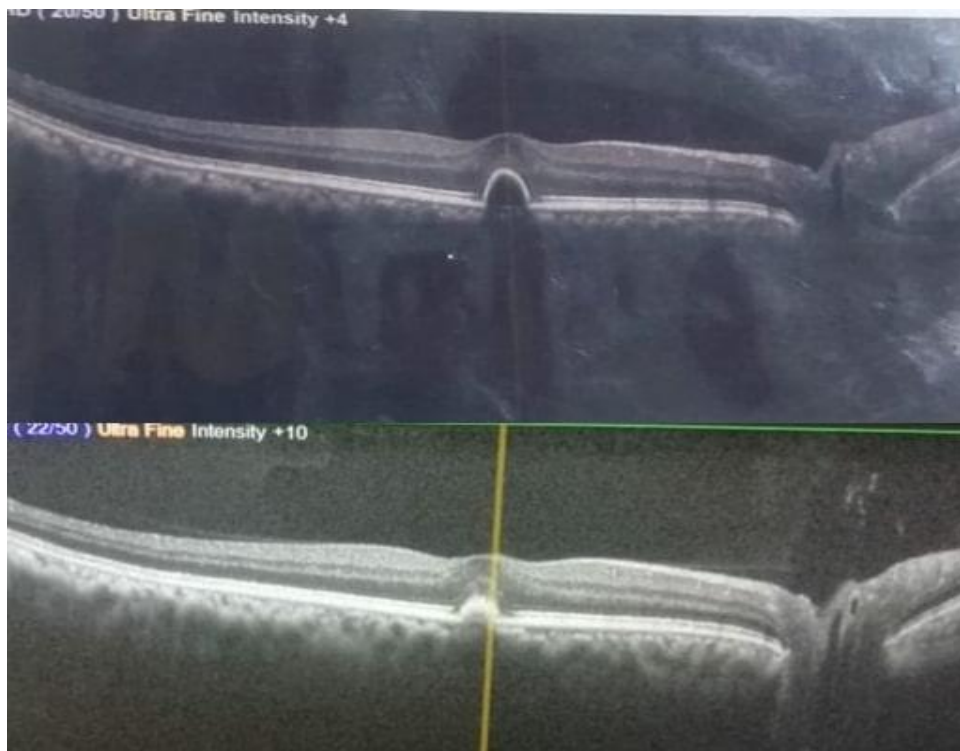**Fig. 1. Pre and post injection OCT after 2 doses of suprachoroidal Anti VEGF at 6<sup>th</sup> week of follow up showing almost complete resolution of serous PED in first patient. PED decreased in height from 566 microns pre injection to 72 microns 6<sup>th</sup> week post injection**



**Fig. 2. Pre and post injection OCT after 2 doses of suprachoroidal Anti VEGF at 6<sup>th</sup> week of follow up showing complete resolution of serous PED in second patient. PED decreased in height from 712 microns pre injection to <50 microns 6<sup>th</sup> week post injection**



**Fig. 3.** Pre and post injection OCT after 2 doses of suprachoroidal Anti VEGF at 6<sup>th</sup> week of follow up showing complete resolution of serous PED in third patient. PED decreased in height from 338 microns pre injection to < 50 microns 6<sup>th</sup> week post injection



**Fig. 4.** Pre and post injection OCT after 2 doses of suprachoroidal Anti VEGF at 6<sup>th</sup> week of follow up showing complete resolution of serous PED in fourth patient. PED decreased in height from 594 microns pre injection to 104 microns 6<sup>th</sup> week post injection

**Table 1. Pre and post injection BCVA in patients diagnosed of recalcitrant serous PED treated with suprachoroidal anti VEGF**

Sr. No	Pre injection BCVA (n=30)	Post injection BCVA (n=30)					
		3rd day	7th day	2nd week	4th week	6th week	8th week
1	6/36	6/36	6/24	6/24	6/18	6/18	6/12
2	6/24	6/24	6/18	6/18	6/12	6/12	6/9
3	6/24	6/24	6/18	6/18	6/12	6/9	6/9
4	6/18	6/18	6/18	6/18	6/12	6/12	6/12
5	6/18	6/18	6/18	6/18	6/12	6/9	6/6
6	6/24	6/24	6/18	6/12	6/12	6/9	6/6
7	6/24	6/24	6/18	6/18	6/12	6/9	6/9
8	6/18	6/18	6/18	6/18	6/12	6/12	6/12
9	6/24	6/24	6/24	6/18	6/12	6/12	6/9
10	6/36	6/36	6/24	6/24	6/18	6/18	6/12
11	6/36	6/24	6/18	6/12	6/12	6/9	6/6
12	6/24	6/24	6/18	6/12	6/9	6/9	6/12
13	6/18	6/18	6/18	6/18	6/12	6/12	6/12
14	6/36	6/36	6/24	6/24	6/18	6/18	6/12
15	6/24	6/24	6/18	6/18	6/12	6/9	6/9
16	6/18	6/18	6/18	6/18	6/12	6/9	6/6
17	6/24	6/24	6/18	6/18	6/12	6/12	6/9
18	6/24	6/24	6/18	6/12	6/12	6/9	6/6
19	6/18	6/18	6/18	6/12	6/12	6/12	6/6
20	6/36	6/36	6/24	6/24	6/18	6/18	6/12
21	6/18	6/18	6/18	6/18	6/12	6/12	6/12
22	6/36	6/24	6/24	6/24	6/18	6/12	6/9
23	6/24	6/24	6/18	6/18	6/12	6/9	6/9
24	6/24	6/24	6/18	6/12	6/12	6/9	6/6
25	6/24	6/24	6/18	6/18	6/12	6/12	6/9
26	6/24	6/24	6/18	6/18	6/9	6/9	6/6
27	6/18	6/18	6/18	6/18	6/12	6/9	6/6
28	6/24	6/24	6/18	6/12	6/12	6/9	6/6
29	6/24	6/24	6/18	6/18	6/12	6/9	6/6
30	6/24	6/24	6/18	6/18	6/12	6/12	6/9

#### 4. DISCUSSION

PED in itself is a non-specific finding, and is generally associated with ocular conditions like CSCR, nAMD, PCV, etc. For the development of serous PED, a spectrum of different mechanisms has been proposed and choroidal hyperpermeability has been implicated in their pathogenesis in the absence of Choroidal neovascularization (CNV) [9]. In 1986, Bird and Marshall introduced the concept of age related reduced hydraulic conductivity of Bruch's membrane. It states that there occurs progressive thickening of Bruch's membrane due to deposition of lipid that increases its hydrophobicity. This interferes with the RPE pump and creates a barrier to the normal flow of fluid and ions across the Bruch's membrane towards the choriocapillaries. With time the fluid

gets collected beneath the RPE leading to its separation [10].

Drusenoid PEDs are formed due to gradual coalescence of pre-existing soft drusen in the setting of AMD. This reduces the hydraulic conductivity of the Bruch's membrane and initiates the cascade of RPE separation [11,12].

Hemorrhagic or fibrovascular PEDs are associated with CNV. The neovascularization slowly gains entrance into the sub-RPE space, breaking through the Bruch's membrane and there it organizes into the fibro-vascular network, subsequently developing into fibrovascular PED. These are "leaky" blood vessels with improper blood-retinal barrier and hence tend to bleed into the sub-RPE space creating haemorrhagic PED [13,14].

**Table 2. Pre and post injection LogMAR BCVA in patients diagnosed of recalcitrant serous PED treated with suprachoroidal anti VEGF (p-value <0.05)**

	Pre injection LogMAR BCVA(n=30)	LogMAR BCVA Post injection (n=30)					
		3rd day	7th day	2nd week	4th week	6th week	8th week
1	0.78	0.78	0.6	0.6	0.48	0.48	0.3
2	0.6	0.6	0.48	0.48	0.3	0.3	0.17
3	0.6	0.6	0.48	0.48	0.3	0.17	0.17
4	0.48	0.48	0.48	0.48	0.3	0.3	0.3
5	0.48	0.48	0.48	0.48	0.3	0.17	0
6	0.6	0.6	0.48	0.3	0.3	0.17	0
7	0.6	0.6	0.48	0.48	0.3	0.17	0.17
8	0.48	0.48	0.48	0.48	0.3	0.3	0.3
9	0.6	0.6	0.6	0.48	0.3	0.3	0.17
10	0.78	0.78	0.6	0.6	0.48	0.48	0.3
11	0.78	0.6	0.48	0.3	0.3	0.17	0
12	0.6	0.6	0.48	0.3	0.17	0.17	0.3
13	0.48	0.48	0.48	0.48	0.3	0.3	0.3
14	0.78	0.78	0.6	0.6	0.48	0.48	0.3
15	0.6	0.6	0.48	0.48	0.3	0.17	0.17
16	0.48	0.48	0.48	0.48	0.3	0.17	0
17	0.6	0.6	0.48	0.48	0.3	0.3	0.17
18	0.6	0.6	0.48	0.3	0.3	0.17	0
19	0.48	0.48	0.48	0.3	0.3	0.3	0
20	0.78	0.78	0.6	0.6	0.48	0.48	0.3
21	0.48	0.48	0.48	0.48	0.3	0.3	0.3
22	0.78	0.6	0.6	0.6	0.48	0.3	0.17
23	0.6	0.6	0.48	0.48	0.3	0.17	0.17
24	0.6	0.6	0.48	0.3	0.3	0.17	0
25	0.6	0.6	0.48	0.48	0.3	0.3	0.17
26	0.6	0.6	0.48	0.48	0.17	0.17	0
27	0.48	0.48	0.48	0.48	0.3	0.17	0
28	0.6	0.6	0.48	0.3	0.3	0.17	0
29	0.6	0.6	0.48	0.48	0.3	0.17	0
30	0.6	0.6	0.48	0.48	0.3	0.3	0.17
Mean	0.604	0.592	0.504	0.458	0.321333	0.259	0.146667

On fundus examination, PEDs appear as well defined dome shaped elevation of RPE, usually within the posterior pole. Serous PEDs have a smooth surface with orangish appearance mean while the drusenoid type have irregular surface with areas of hyperpigmentation. In fibrovascular and haemorrhagic type, due to the presence of CNV or their variants namely Retinal angiomatous proliferation (RAP) and Idiopathic polypoidal chroidal vasculopathy (IPCV), retinal haemorrhages are common finding along with intraretinal or subretinal fluid. As most of the PEDs occur due to the pathophysiological processes taking place beneath the RPE, hence indocyanine green angiography (ICGA) remains the diagnostic modality of choice. It can also differentiate between vascularized and non-vascularized PED. On fundus fluorescein angiography (FFA), serous PEDs exhibit early

hyperfluorescence with increasing intensity within a well-defined area whereas the drusenoid type show late staining. Both types do not demonstrate any leakage in contrast to the fibrovascular type where one can notice leakage with stippled or lacy hyperfluorescence based on whether CNV is "occult type" or "classic type" respectively.

By OCT one can identify the contents of PED and monitor response to treatment. Drusenoid type may be iso-fluorescent or hyperacute-fluorescent surrounded by a well-defined hypoauto-fluorescent border. Vascular types are atypical and FAF imaging is not well defined hence further FAF studies are required to establish any specific pattern [4,15].

PEDs tend to have an indolent course and generally remain unchanged over prolonged

periods. Intravitreal anti-VEGFs have been tried for the treatment of fibrovascular types but they are also associated with resistance to therapy. PDT and laser photocoagulation have also been tried with some success. Studies have reported that photothrombotic to the vascular components under ICGA guidance followed by application of laser to feeder vessels have shown satisfactory results in patients of vascular PED.

Presently, no treatment has proven effective against serous and drusenoid PED and they may eventually become atrophic and cause permanent visual deprivation. Chang B et al have tried to treat serous PEDs with laser grid or photocoagulation but with disappointing results [16]. Yannuzzi et al tried to treat serous PEDs by various modalities like laser photocoagulation, intravitreal anti VEGFs with no satisfactory results [17]. Verteporfin photodynamic therapy (PDT) has also been tried for serous PED by Zayit-Soudry et al and Pece et al has been proved to be harmful, increasing the risk of RPE tear, and sudden visual acuity decrease [18,19].

Many even have underlying clinically undetectable CNV hence may progress to their fibrovascular counterpart [20-22].

Serous avascular PED in clinical practice is managed conservatively with no defined therapeutic indications. Their resistance to treatment leads to patient dissatisfaction with visual compromise. This calls for the collaborative effort from the physician's part to conduct studies and experiments in order to land up with a successful management protocol for such patients.

In this study we dealt with similar patients with recalcitrant PED who responded to the suprachoroidal injection of anti VEGF as seen by decrease in mean LogMAR visual acuity from 0.59 to 0.15 and resolution of PED on SD-OCT. With the continuous advancements in the medical field a novel route of drug administration; i.e.; suprachoroidal drug delivery, is now under trial run for the management of multiple posterior segment pathologies. Larger volumes, upto 1mL, can be tolerated in SCS which is much larger than required to achieve therapeutic levels hence can also be utilized as a drug depot system. Drug delivery through SCS can even bypass the outer blood retinal barrier and can be utilized to target the RPE. Small gauge needles long enough only to penetrate sclera (0.7-1.0 mm) can be used to perform SCS drug delivery.

Taking into consideration such evidences, suprachoroidal drug delivery of anti-VEGF and their promising effects have been put forward through this study [23].

All the cases presented with blurred vision with central scotoma which is a usual presentation of serous PED. All of them had taken treatment as some form of intravitreal anti-VEGF along with conservative management but had no or poor visual recovery post injection. Resultant was a recalcitrant serous PED which was quite troublesome. All the patients were then undertaken for suprachoroidal anti-VEGF bevacizumab under topical anaesthesia.

The patients stated that during injection, they experienced more pain as compared to the intravitreal injections which they had received in past. There was a transient rise in intraocular pressure which was quickly recovered and no pressure lowering drug was needed other than the stat dose of oral acetazolamide 500mg. No adverse events like floaters, RPE tear, ocularinfections were experienced. During follow-up visits, the visual recovery was significant and was maintained.

## 5. CONCLUSION

With this study we concluded that suprachoroidal route of drug delivery is a practical and promising approach of treatment in patients of recalcitrant serous PED. It is rather safe and can be considered for other retinal pathologies.

Randomized control trial are required to conclude and establish suprachoroidal drug delivery systems as an effective line of management of recalcitrant PED.

## 6. LIMITATION

- Small number of participants.
- Duration of follow up is less.
- Only 2 OCTs one pre and one post injection were performed. Further similar studies should have more frequent OCT imaging.

## CONSENT

As per international standard or university standard, patient(s) written consent has been collected and preserved by the author(s).



## ETHICAL APPROVAL

As per international standard or university standard written ethical approval has been collected and preserved by the author(s).

## COMPETING INTERESTS

Authors have declared that no competing interests exist.

## REFERENCES

1. Zayit-Soudry S, Moroz I, Loewenstein A. Retinal pigment epithelial detachment. *Surv Ophthalmol.* 2007;52(3):227-43.
2. Khochtali S, Ksiao I, Megzari K, Khairallah M. Retinal pigment epithelium detachment in acute vogt-koyanagi-harada disease: An unusual finding at presentation. *Ocul Immunol Inflamm.* 2019;27(4):591–594.
3. Wolfensberger, Thomas J, Adnan Tufail. Systemic disorders associated with detachment of the neurosensory retina and retinal pigment epithelium. *Current Opinion in Ophthalmology.* 2000;11(6):455-461.
4. Mrejen S, Sarraf D, Mukkamala SK, Freund KB. Multimodal imaging of pigment epithelial detachment: a guide to evaluation. *Retina.* 2013;33(9):1735-1762.
5. Gonzalez A, Khurshid G. Treatment of retinal pigment epithelial detachment secondary to exudative age-related macular degeneration. *Am J Ophthalmol Case Rep.* 2017;9:18-22. DOI: 10.1016/j.ajoc.2017.12.004. PMID: 29468211; PMCID: PMC5786863.
6. Krohn J, Bertelsen T. Corrosion casts of the suprachoroidal space and uveoscleral drainage routes in the human eye. *Acta Ophthalmol Scand.* 1997;75(1):32–35.
7. Ferrara D, Mohler KJ, Waheed N, et al. En face enhanced-depth swept-source optical coherence tomography features of chronic central serous chorioretinopathy. *Ophthalmology.* 2014;121(3):719–26.
8. Seiler GS, Salmon JH, Mantuo R, Feingold S, Dayton PA, Gilger BC. Effect and distribution of contrast medium after injection into the anterior suprachoroidal space in ex vivo eyes. *Invest Ophthalmol Vis Sci.* 2011;52(8):5730–36.
9. Goto S, Gomi F, Ueno C, Nishida K. Reduced-fluence photodynamic therapy for subfoveal serous pigment epithelial detachment with choroidal vascular hyperpermeability. *Am J Ophthalmol.* 2012;154(5):865-71.
10. Bird AC, Marshall J. Retinal pigment epithelial detachments in the elderly. *Trans Ophthalmol Soc UK.* 1986;105(Pt 6):674–82.
11. Casswell AG, Kohlen D, Bird AC. Retinal pigment epithelial detachments in the elderly: classification and outcome. *Br J Ophthalmol.* 1985;69:397–403.
12. Bressler NM, Silva JC, Bressler SB, et al. Clinicopathologic correlation of drusen and retinal pigment epithelial abnormalities in age-related macular degeneration. *Retina.* 1994;14:130–42.
13. Macular photocoagulation study group. Sub foveal neovascular lesions in age-related macular degeneration. Guidelines for evaluation and treatment in the Macular Photocoagulation Study. *Arch Ophthalmol.* 1991;109:1242–57.
14. Young RW. Pathophysiology of age-related macular degeneration. *Surv Ophthalmol.* 1987;31(5):291–306.
15. Gass JD, Norton EW, Justice J Jr. Serous detachment of the retinal pigment epithelium. *Trans Am Acad Ophthalmol Otolaryngol.* 1966;70:990–1015.
16. Chang B, Yannuzzi LA, Ladas ID, et al. Choroidal neovascularization in second eyes of patients with unilateral exudative age-related macular degeneration. *Ophthalmology.* 1995;102:1380-6.
17. Yannuzzi LA. Retinal pigment epithelial detachment. *J Fr Ophthalmol.* 1989;12:761-74.
18. Zayit-Soudry S, Moroz I, Loewenstein A. Retinal pigment epithelial detachment. *Surv Ophthalmol.* 2007;52(3):227-243.
19. Pece A, Introini U, Bottoni F, et al. Acute retinal pigment epithelial tear after photodynamic therapy. *Retina.* 2001;21:661-5.
20. Hoerster R, Muether PS, Sitniska V, Kirchhof B, Fauser S. Fibrovascular pigment epithelial detachment is a risk factor for long-term visual decay in neovascular age-related macular degeneration. *Retina.* 2014;34:1767–73.
21. Verteporfin photodynamic therapy study group. Verteporfin therapy of subfoveal choroidal neovascularization in age-related macular degeneration: two-year results of a randomized clinical trial including lesions with occult with no classic choroidal neovascularization--verteporfin in photodynamic therapy report 2. *Am J Ophthalmol.* 2001;131:541-560.

22. Elman MJ, Fine SL, Murphy RP, et al. The natural history of serous retinal pigment epithelium detachment in patients with age-related macular degeneration. *Ophthalmology*. 1986;93:224–30.
23. Patel SR, Lin AS, Edelhauser HF, Prausnitz MR. Suprachoroidal drug delivery to the back of the eye using hollow microneedles. *Pharm Res*. 2011;28:166–176.

© 2023 Datta et al.; This is an Open Access article distributed under the terms of the Creative Commons Attribution License (<http://creativecommons.org/licenses/by/4.0>), which permits unrestricted use, distribution, and reproduction in any medium, provided the original work is properly cited.

*Peer-review history:*

*The peer review history for this paper can be accessed here:*

<https://www.sdiarticle5.com/review-history/99193>