

Ultrasound-guided inferior alveolar nerve block in donkeys

Adel M. Sobhy¹, Ahmed G. Nomir², Ahmed N. El-khamary¹, AbdelRahaman A. Abo-rawash³, Ashraf Shamaa⁴, Mostafa M. Kassem⁵

¹Department of Surgery, Faculty of Veterinary Medicine, Damanhour University,

²Department of Anatomy Faculty of Veterinary Medicine, Damanhour University,

³Department of Pathology Faculty of Veterinary Medicine, Damanhour University,

⁴Department of Surgery, Faculty of Veterinary Medicine, Cairo University,

⁵Department of Surgery, Faculty of Veterinary Medicine, Alexandria University

ABSTRACT

The objective of the present study was to describe an ultrasound-guided technique of the inferior alveolar nerve block in donkeys. Preliminary study involving performing descriptive dissection of the mandibles of three fresh donkey heads as a base for ultrasound guided injection of a colored dye just beside the nerve in another six intact fresh donkey head. Assessments of the technique and the most appropriate approach were recorded. Color doppler flow ultrasound was used to guide the needle insertion for inferior alveolar nerve block in six alive donkeys. A full anesthetic evaluation was performed. The surgical anatomy of the ventral mandible of the donkey was similar to the horse. The course and relations of the inferior alveolar nerve and blood vessels were recorded. The proper location of ultrasound transducer with the most appropriate diagnostic angle was determined and the point of needle insertion with the least tissue invasiveness regarding the preliminary study results were also documented. The color flow doppler offers great assistance in locating the blood vessel accompanying inferior alveolar nerve and make approaching the nerve block more fast, feasible and efficient. The clinical anesthetic evaluation showed a hundred percent efficiency and no post anesthetic complications. Advancement of veterinary diagnostic tools at the same time with low costs and readily availability make the use of ultrasound a reliable option for guidance in nerve blocks especially for those deep nerves related with vital structures.

Keywords: Donkey; Inferior alveolar nerve; Ultrasound guided nerve block; Local analgesia

1. Introduction

Mandibular fracture, dental injuries, mandibular periodontal and endodontal diseases and other surgical disorders of mandible may require surgical intervention under the effect of regional or general anesthesia (Ducharme, 2004). General anesthesia is associated with high anesthetic risks. The safer and more reliable option; regional analgesia plays a fundamental role in providing the required anesthesia and analgesia either in the field or in animals with high risk of anesthetic complications (Lizarraga et al., 2004). Regional analgesic techniques provide an immediate pain relief, very smooth recovery and no hospital stay in contrast to general anesthesia (Singelyn et al., 1998; Capdevila et al., 1999). Various factors can markedly affect the success and outcome of peripheral nerve blocks. These include the exact location of the nerve to be blocked and how it may be reached safely and accurately and the type and amount of the local anesthetic used for the block. (Futema et al., 2002). The anatomy of the mandibular region in equines is complicated.

*Corresponding author: Adel Sobhy

E-mail address: adelsobhy2014@vetmed.dmu.edu.eg

Department of Surgery, Faculty of Veterinary Medicine, Damanhour University, Damanhour 22511, El-Behera, Egypt

P ISSN: 2636-3003 EISSN: 2636-2996

Received: October 20, 2019; Received in revised form: November 7, 2019; accepted: October 19, 2019.

The inferior alveolar nerve (IAN) adheres to the medial aspect of the mandible with the inferior alveolar artery lateral to it. The mylohyoid nerve innervating the mylohyoid and digastric muscles lied caudal to the IAN. The lingual nerve lies ventromedial to the IAN, giving branches to the base of the tongue (Henry et al., 2014). The IAN is a main branch of the mandibular nerve. It runs in a shallow groove on the medial aspect of the mandible until enter to the mandibular foramen as the mental nerve with six or furthermore branches. (Dyce et al., 2010 and Budras et al., 2012). The IAN forms a complex with the inferior alveolar blood vessels (IABv). The inferior alveolar complex (nerve and blood vessels) runs between the internal pterygoid muscle and the mandible and enter the mandibular canal together (Dyce et al., 2010 and Budras et al., 2012). Inferior alveolar nerve of both sides of the mandible provides enervation to the ipsilateral canine, premolars, molars, incisor teeth, skin and lip rostral to the mental foramen. Inferior alveolar nerve block desensitizes these structures and provide analgesia adequate for surgery (Doherty and Schumacher 2011; Ashdown and Done 2011).

Inferior alveolar nerve block has more than one approach. The ventral approach is performed by advancing a 12.5 cm spinal needle transcutaneous at ventral ramus while maintaining it in close proximity to the medial mandibular periosteum, underneath the medial pterygoid muscle, until the convexity of the dorsal margin of the foramen is contacted (Fletcher, 2004 and Tremaine, 2007). Fifteen to twenty cc of local anesthetic solution is infiltrated in the area as described by (Fletcher, 2004 and Henry et al., 2014). Complete desensitization within 15 to 30 minutes is recorded (Woodie, 2013). Other reported approaches include the caudal approach (Fletcher, 2004) and intraoral approach (Henry et al., 2014). These approaches comprise insertion of the needle either from the interior of mouth cavity or at the caudal angle of the mandible to reach the target nerve before entering the mandibular foramen.

Ultrasound guided nerve block (UGNB) is a recent advanced technique. The ultrasound provides the operator with an image of either the nerve or in other instances the blood vessels associate the nerve with the aid of color flow Doppler. UGNB offers an accurate needle direction and position and monitor the distribution of the local anesthetic solution in real-time. This technique also has the potential advantages of improved nerve block efficacy, faster approach, and smaller volumes of local anesthetic solution required (Marhofer et al., 1997, 1998, 2005 and Grau, 2005).

2. Material and methods

2.1. Animals

The present experimental study was carried out on nine fresh heads of donkey cadavers prepared for undergraduate student anatomy sessions, and six healthy donkeys of both sexes with average body weight 150-200 kg and age 4- 8 years for the clinical experimental study. All procedures were performed at the department of surgery, faculty of veterinary medicine, Damanhur University and obtained an ethical approval 3/10-

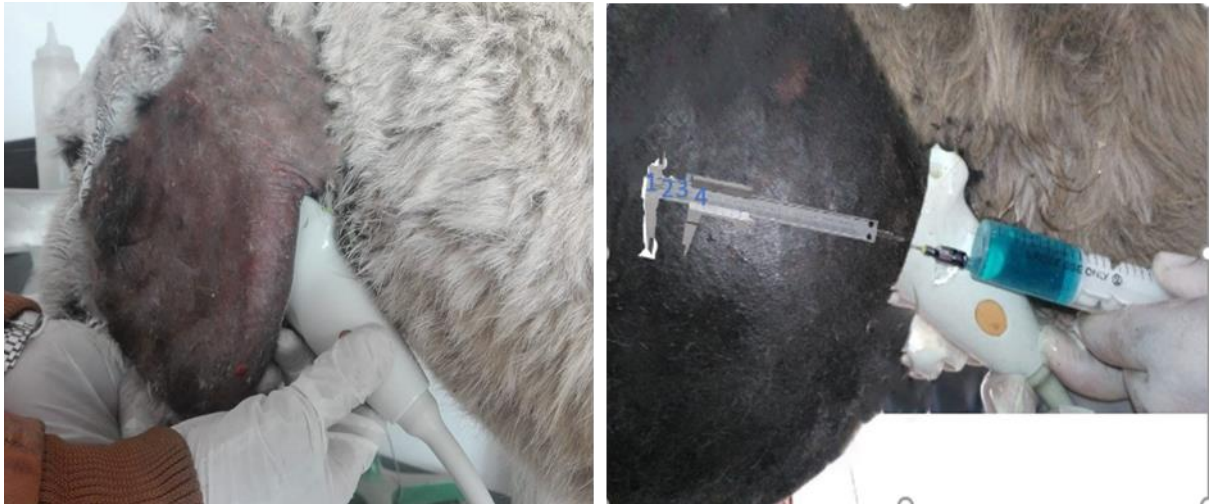

Figure 1: The caudal approach of injection of methylene blue under direct visualization with ultrasound.

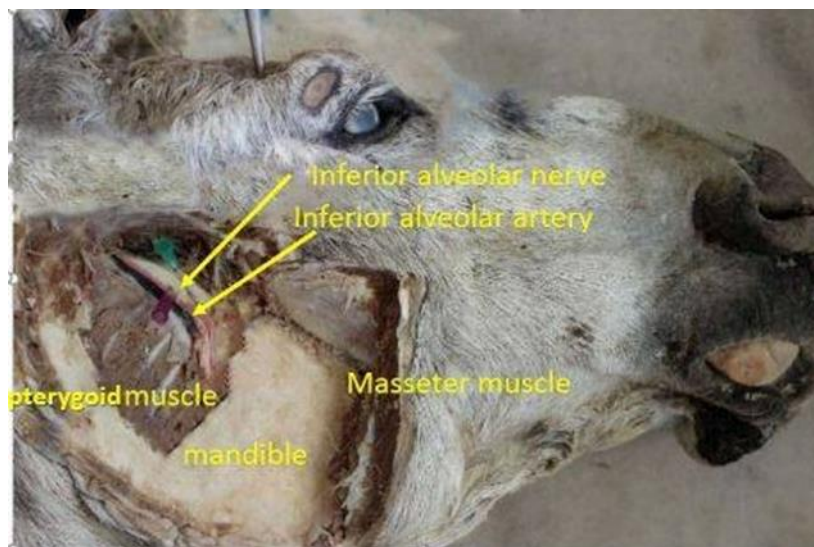


Figure 1: Anatomical dissection of the mandibular area that demonstrating inferior alveolar nerve, inferior alveolar artery, medial pterygoid, mandibular bone and masseter muscle.

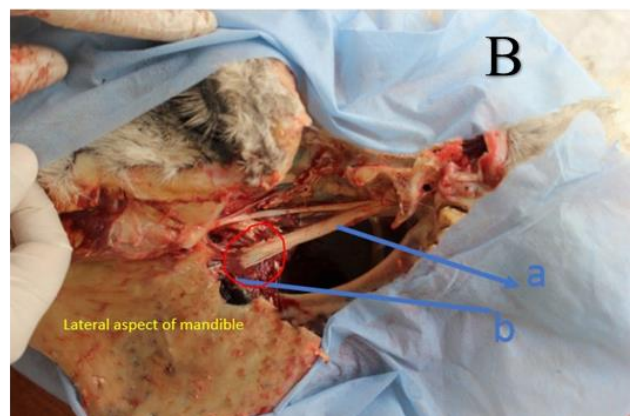
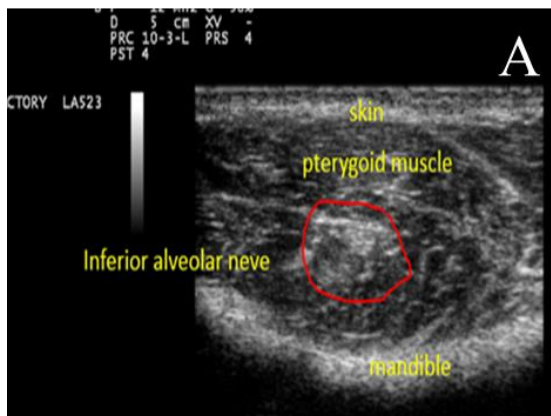


Figure. 1: (A). The Ultrasonogram of the medial aspect of the mandible with the caudal approach in cadaver. The red circle demonstrating the inferior alveolar nerve. (B) shows anatomical dissection from the lateral aspect of the mandible.

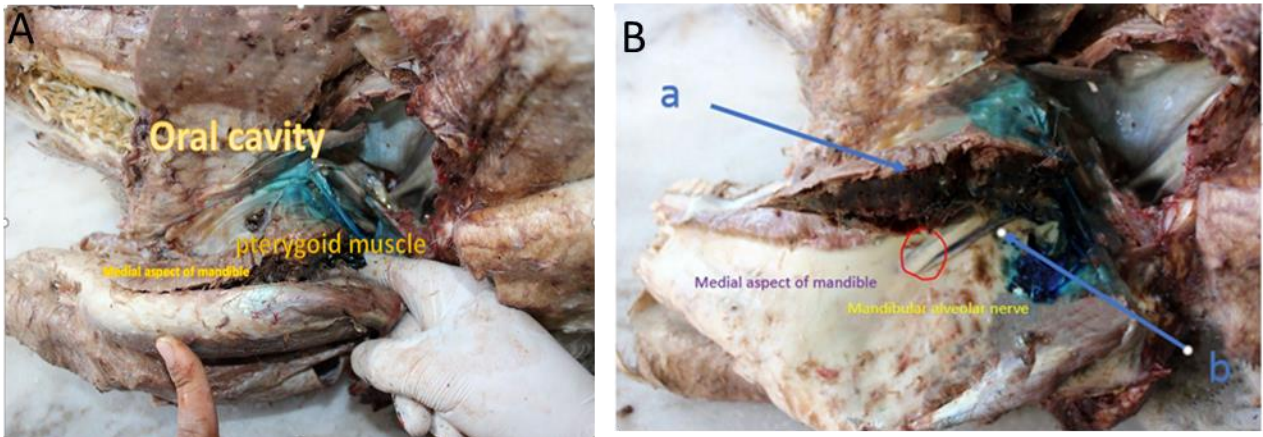


Figure. 4: Anatomical dissection from the medial aspect of the mandible after injection of the mandibular nerve by methylene blue. (a) pterygoid muscle, (b) inferior alveolar nerve.

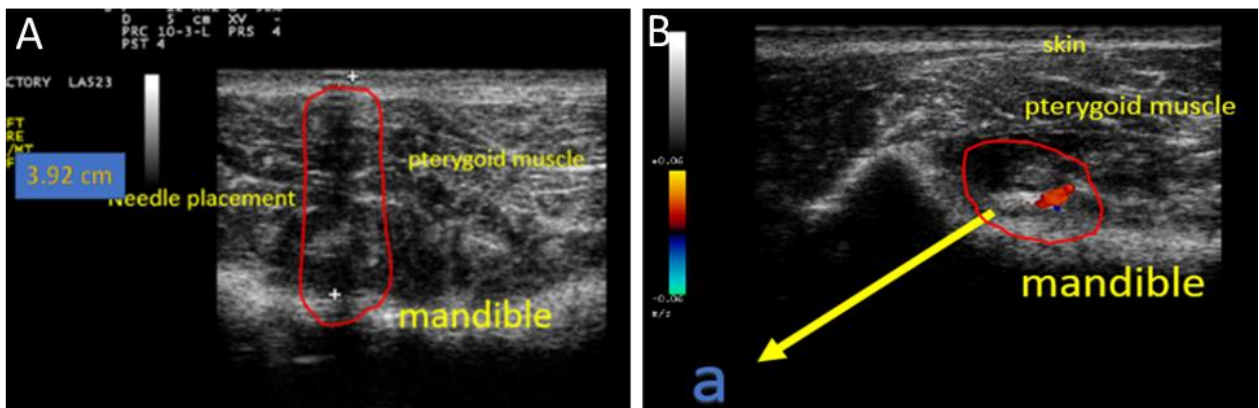


Figure. 5: A) Shows needle penetration through the caudal aspect of the mandible beneath the pterygoid muscle (the red circle marks the distance to the target nerve). The distance from skin to the nerve is 3.92cm. B) The red circle demonstrating the mandibular artery and associated inferior alveolar nerve (the site of LA injection).

2018-surg for the clinical approach of experimental animals, Faculty of Veterinary Medicine, Damanhour University, Egypt.

2.2. Preliminary descriptive anatomical study

A skin incision at the rostral edge of the mandible, skin was reflected with the underlining fascia. Further dissection of the fascia to expose the muscles at the medial aspect of the mandible (The medial pterygoid and the lateral pterygoid muscles). Further dissection of pterygoid muscles to expose the mandibular foramen and the vascular and neural structure in this region. The distance from the caudal margin of the ramus mandible to the mandibular foramen in all animals were measured by using of *Vernier* caliper (0-150 mm) and tabulated.

2.3. Experimental location of the IAN with the guidance of ultrasound imaging technique

The mandibular region of six intact, fresh cadaver donkey heads were prepared for ultrasonographic examination. Ultrasonographic examination was done by 8 MHz linear array transducer (*ESAOTE my lap 30, Italy*). The transducer was applied in the caudomedial aspect of the mandible (Caudal approach). The area was scanned with the direction of ultrasound beam forward and medial until the mandibular foramen was identified. The distance from skin to target nerve was determined by ultrasound measurement. An eighteen-gauge 10 cm spinal needle is advanced transcutaneous craniomedially from the caudal edge of the mandible to the mandibular foramen under direct visualization of the needle. Two cc of methylene blue solution was injected in both side of the mandible (Fig. 1).

The caudal mandibular area was dissected two hours later to assess accuracy of nerve location through examination of the area stained with the methylene blue dye according to O'Neil et al. (2014). The results of the twelve attempts were recorded and tabulated for statistical analysis. Scoring of nerve staining on a scale of 0 (non-stained), 1 (partially stained) and 2 (completely stained). Other evaluation processes included recording of the appropriate position and angle of ultrasound transducer, degree of tissue invasiveness, the optimal point of needle insertion, and feasibility of the procedure.

2.4. Ultrasound-guided inferior alveolar nerve block

Six donkeys were sedated using xylazine in a dose 1.1 mg/kg iv. For performing clinical experiments, the caudal mandibular area was clipped, shaved and aseptically prepared for anesthetic procedure. The sensation in the lower lip and chin was verified via pinprick needle. A half cc of lidocaine HCl 2% was injected for analgesia at the point of transcutaneous needle insertion. The ultrasound transducer was positioned with 35-45° angle to reveal the mandibular foramen. The anesthesia needle is advanced craniomedially through the skin and underlying muscles to the foramen. The anesthetic syringe is attached to the needle hub, aspiration to eliminate vascular puncture, then ten cc of lidocaine 2% local anesthetic was injected. The onset of analgesia, duration of action was recorded and tabulated for each animal. Analgesia was scored on a scale of 0 (no analgesia), 1 (analgesia achieved). Minor surgical procedure of the lower lip (suturing of an incisional wound) was performed.

3. Results

3.1. Surgical anatomy of the inferior alveolar nerve in donkey

The medial pterygoid and lateral pterygoid muscles were identified at the medial aspect of the mandible. Further dissection showed the tendon of digastricus muscle and lateral pterygoid conjugated with the medial pterygoid muscle forming groove; the pterygoid mandibular space. The mandibular foramen is located at the dorsal part of mandible parallel to the buccal occlusion surface of the oral cavity. The inferior alveolar nerve runs at the medial aspect of mandible to the mandibular foramen. The nerve appeared as a large white brand. the inferior alveolar artery was identified related to the IA nerve forming a nerve-vessels complex. the distance from skin to the inferior alveolar nerve at caudal edge of the mandible =4cm (Fig. 2)

3.2. Experimental location of the IAN with the guidance of ultrasound

The mandibular inferior alveolar nerve was successfully identified in both sides of all cadaver heads as a bright hyper-echogenic structure located close to the medial aspect of the mandible. The mandibular inferior alveolar artery was identified as oval, round hypo-echoic at central with a hyper-echogenic rim. Ultrasound transducer caudal approach injection of the mandibular inferior alveolar nerve in the cadaver head was practical and accurate. High scoring of staining with ultrasound (2/12=25% partially stained (figure, 3) and 9/12=75% completely stained (figure,4). The blood vessels in this area (mandibular artery) were identified. In all cadaver heads, it was possible to identify the groove space at the caudal aspect of the mandible as well as observe the needle where it penetrates through the tissue to become near the mandibular inferior alveolar nerve. Distance between skin to mandibular foramen (4±0.2) cm

3.3. Ultrasound-guided inferior alveolar nerve block

Doppler Ultrasound-guided caudal approach demonstrates the mandibular foramen as hypoechoic area while the inferior alveolar nerve appeared as

hyperechoic threads surrounded by hypo-echoic mandibular artery. The inferior alveolar artery was found to be colored and pulsatile. In all cases, it was recorded the advancing of the needle toward the target of mandibular nerve and distance from skin to target nerve with mean SD 4±0.2 cm. The dose local anesthetic solution was injected for the nerve blockage 10ml of lidocaine 2%. The analgesia was achieved after 13±3 minutes and duration of anesthesia taken from 60±15 minutes, surgical anesthesia assured by no response to pinprick test at the lower lip and chin and lower lip was dropped. All animals showed no pain response to injury and surgical intervention all over the required time for the procedure.

4. Discussion

Inferior alveolar nerve block is a challenging procedure. Both ventral and caudal blind approaches comprise various technical difficulties and frequent intra and post anesthetic complications. The individual anatomical variations are a serious issue for the success of the nerve block. Tissue invasiveness, destruction and puncture of blood vessels and trauma of the nerves (O'Neil et al., 2014; Hagag and Tawfik 2018). The present study was based on a rationale of offering a reliable, feasible and an accurate technique for inferior alveolar nerve block in donkeys.

Several approaches are described for the inferior alveolar nerve block in different animal species. In pet animals, the intraoral approach is a common technique (Goudie-DeAngelis et al., 2016) and the extraoral ventral approach is not more common (Beckman, 2007). In cattle the ventrocaudal extraoral approach (Ducharme, 2004) and intraoral approach was reported in cadavers (Nazih and El-Sherif, 2018). In equine, more than one approach is reported; the caudal, the ventral extraoral (Fletcher, 2004) and the intraoral approach (Henry et al., 2014). Ultrasound guidance is a common assistance process used in several superficial and deep nerve block in animal species (O' Morrow, 2010; El-Khamary et al., 2017). To our knowledge, the present study is the first article describing the use of ultrasound as a guidance for the inferior alveolar nerve block in donkeys.

An in detail anatomical discription of the inferior alveolar nerve and its relation to adjacent blood vessels and tissues are described in donkeys in the current study. The mandibular foramen was located on the medial aspect of the mandible and the best site to reach it was found to be from pterygomandibular space, as it was the nearest point to the inferior alveolar (4cm) nerve rather than 12cm distance in the ventral approach as mentioned by (Fletcher, 2004 and Tremaine, 2007). Stasz et al., (2008) reported a similar result in horse. The caudomedial aspect of the mandible (pterygomandibular space) was the proper site for ultrasound transducer application for better visualization of the nerve as described by Hannan et al., (1999).

Fine and adequate distribution of the methylene blue dye around the inferior alveolar nerve in the preliminary experiments indicated the proper administration and accuracy to reach the nerve and qualify the approach for clinical application. The distance measured from the outer skin to the site of injection at the mandibular foremen was ranged from 3 to 4 cm in average. The distance differs according to the age, sex and body conformation of the animal.

In the clinical study, ultrasound was beneficial to identify the mandibular nerve that appeared as a hyperechoic band and surrounded by a hypoechoic pulsating area of the inferior alveolar artery that declared by doppler color flow. Clinically, the lower lip of the animal was dropped after 13±3 minutes of administration. This time of onset considered short Hannan et al., (1999) compared to the onset of analgesia with the extraoral ventral approach averaged 15-30 minutes Marhofer et al., (1997, 1998, 2005); Grau (2005); Stasz et al., (2008).

Ultrasound-guided technique of inferior alveolar nerve block is found to be accurate either more than the traditional ventral approach. The techniques provide the ability to manipulate the needle under direct guidance of ultrasound real time visualization and infiltration of the local anesthetic directly around the nerve and increase safety and efficiency of the procedure. Perlas et al., (2003) reported similar results associated with the use of ultrasound in assisting regional nerve blocks. Onset of analgesia also decreased in contrast to results reported by Williams et al., (2003) and Echeverry et al., (2012). A faster onset was obtained despite a reduced volume of local anesthetic is another advantage of the present technique.

Conclusion

Color doppler flow ultrasound offers great assistance for more accurate inferior alveolar nerve block in donkeys, reduced the volume of local anesthetic needed, resulted in faster onset of action and reduced risk of local and systemic toxicity. These results elect this approach for wide use and evaluation by veterinarians in clinics and in the field.

Competing Interests

The authors have no conflict of interest.

References

Ashdown, R.R., Done, S.H. 2011. Color atlas of veterinary anatomy: volume 2, the horse. Mosby Publishing, Philadelphia.

- Beckman, B. 2007. Regional nerve blocks- key to delivering quality dental care. DVM Newsmagazine september ; 2-8.
- Budras, K.D., Sack, W.O., Röck, S. 2012. Anatomy of the horse. 6th Ed., Schlu^{ter} tersche Verlagsgesellschaft mbH & Co, Hannover, Germany.
- Capdevila X, Barthalet Y, Biboulet P et al., 1999. Effects of perioperative analgesic technique on the surgical outcome and duration of rehabilitation after major knee surgery. *Anesthesiology* 91, 8–15.
- Doherty T, Schumacher J. 2011. Dental restraint and analgesia. In: Easley J, Dixon PM, Schumacher J. *Equine dentistry*. New York: Saunders-Elsevier Limited, 241-244.
- Ducharme GN. 2004. Surgical diseases of the oral cavity. In: Susan L Fubini, Norm G Ducharme, editors. *Farm animal surgery*. USA: Saunders. 664 p.
- Dyce, K.M., Sack, W.O., Wensing, C.J.G. 2010. *Textbook of Veterinary Anatomy*, Fourth Edition. Elsevier. Missouri. USA. Pp. 321-323
- Echeverry, D.F., Laredo, F.G., Gil, F. et al., 2012. Ultrasoundguided 'two-in-one' femoral and obturator nerve block in the dog: an anatomical study. *Vet. Anaesth. Analg.* 39, 611–617.
- El-Khamary, A., Nazih, M., El-Sherif, M., Senosy, W. 2017. Ultrasound-Guided Pudendal Nerve Block in Male Donkeys. *J Vet Med Res.* 4: 1103.
- Fletcher, B.W. 2004. How to Perform effective equine dental nerve blocks. *Am. Ass. of Equine Practnrs.* 50, 233-236.
- Futema, F., Tabacchi, D., Costa, J.O. et al., 2002. A new brachial plexus block technique in dogs. *Vet. Anaesth. Analg.* 29, 133–139.
- Goudie-DeAngelis, E.M, Snyder, C.J., Raffae, M.R., David, F.H. 2016. A pilot Study comparing the accuracy of two approaches to the inferior alveolar nerve block in canine cadavers. *Intern. J. Appl. Res. Vet. Med.* 14, (1), 49-58.
- Grau, T. 2005. Ultrasonography in the current practice of regional anaesthesia. *Best. Pract. Res. Clin. Anaesthesiol.* 19, 175–200
- Hagaga, u, Tawfik, M. 2018. Blind versus ultrasound-guided maxillary nerve block in donkeys, *Vet. Anaes. Analg.* 45, 103:110
- Hannan, L., Reader, A., Nist, R., Beck, M. and Meyers, W.J., 1999. The use of ultrasound for guiding needle placement for inferior alveolar nerve blocks. *Oral Surgery, Oral Med., Oral Pathol., Oral Radiol., and Endodontol.* 87(6), 658-665.
- Henry, T., Pusterla, N., Guedes, A.G., et al., 2014. Evaluation and clinical use of an intraoral inferior alveolar nerve block in the horse. *Equine Vet. J.* 46(4),706–710.
- Lizarraga, I, Sumano, H., Brumbaugh, G. 2004. Pharmacologic and pharmacokinetic differences between donkeys and horses. *Equine Vet. Educ.* 16, 102-112.
- Marhofer, P., Greher, M., Kapral, S. 2005. Ultrasound guidance in regional anaesthesia. *Brit. J. Anaes.* 94 (1), 7–17.
- Marhofer, P., Schrogendorfer, K., Koinig, H., Kapral, S., Weinstabl, C., Mayer, N. 1997. Ultrasonographic guidance improves sensory block and onset time of three-in-one blocks. *Anesth. Analg.* 85, 854–7.
- Michela, R.E., Blanco-Murcia, J., Villaescusa, F.A. et al., 2014. Ultrasound-guided anesthetic blockade of the pelvic limb in calves. *Vet. J.* 200, 434-439.
- Nazih, M.A., El-Sherif, M.W. 2018. An Intraoral Approach for Mandibular Alveolar Nerve Block in Cattle: Cadaveric Study. *J. Vet. Med. Res.* 5(3), 1126
- O'Neill, H.D., Garcia-Pereira, F.L., Mohakumar, P.S. et al., 2014. Ultrasound-guided injection of the maxillary nerve in the horse. *Equine Vet. J.* 46, 180-184.
- O' Morrow C. 2010. Advanced dental local nerve block anesthesia. *Can Vet J.* 51, 1411-1415.
- Perlas, A., Chan, V.W., Simons, M. 2003. Brachial plexus examination and localization using ultrasound and electrical stimulation: a volunteer study. *Anesthesiology*, 99,429–435.
- Singelyn, F.J., Deyaert, M., Joris, D. et al., 1998. Effects of IV PCA with morphine, continuous epidural analgesia and continuous 3 in 1 block on postoperative pain and knee rehabilitation after unilateral total knee arthroplasty. *Anesth. Analg.* 87, 88–92
- Staszuk, C., Bienert, A., Bumer, W., Feige, K., Gasse, H. 2008. Simulation of local anaesthetic nerve block of the infraorbital nerve within the pterygopalatine fossa: anatomical landmarks defined by computed tomography. *Res. Vet. Sci.* 85, 399-406.
- Tremaine, W. H. 2007. Local analgesic techniques for the equine head *Equine vet. Educ.* 19 (9), 495-503.
- Williams, B.A., Kentor, M.L., Vogt, M.T., et al., 2003. Economics of nerve block pain management after anterior cruciate ligament reconstruction: potential hospital cost savings via associated post anesthesia care unit bypass and same day discharge. *Anesth Analg.* 97,1518–1523.
- Woodie, B.J. 2013. How to Use Local and Regional Anesthesia for Procedures of the Head and Perineum in the Horse. *AAEP PROCEEDINGS* 59, 464 – 466.