

Functional Outcome Analysis of Cubitus Varus Deformity Treatment in Children undergoing Modified French Osteotomy with Technical Modification: A Retrospective Cohort Study

MADHUSUDAN MISHRA¹, SWAGAT MAHAPATRA², VINEET KUMAR³, PANKAJ AGGARWAL⁴, SACHIN AVASTHI⁵, MOHD AMMAR ASLAM⁶, PRABHAT KUMAR⁷



ABSTRACT

Introduction: Lateral closing wedge osteotomy is an accepted correction method for cubitus varus deformity. The techniques used to fix the osteotomy mostly lead to either angulation or loss of correction during the final tightening of the Stainless Steel (SS) wire at the osteotomy site. The records for patients undergoing two modifications in a conventional modified French Osteotomy were analysed. Four wires, two proximal and two distal to the osteotomy site for precision and guided compression over the other additional Kirschner wire (K-wire) at the osteotomy site, were the two modifications in these patients.

Aim: To analyse the functional outcome of cubitus varus deformity in children treated with technical modifications of modified French osteotomy.

Materials and Methods: This was a retrospective cohort study done at the Department of Orthopaedics, Dr. Ram Manohar Lohia Institute of Medical Sciences, Lucknow, Uttar Pradesh, India. The study duration was three years (from April 2019 to April 2022). A total of 34 cubitus varus deformity patients were included in this study who were operated with lateral closing wedge-modified French osteotomy with technical modification by K-wires. The patients were followed-up for a minimum of six months. The results were analysed using Quick Disabilities of the

Arm, Shoulder and Hand (DASH) and Flynn's criteria. Statistical Package for the Social Sciences (SPSS) version 21.0 was used and p-value<0.05 was considered statistically significant.

Results: Twenty-three (67.65%) cases were male, and 11 (32.35%) were female. Twenty-eight (82.4%) patients were children aged 5 to 10 years, 20 (58.8%) cases involved a right-sided deformity, while the remaining 14 (41.2%) had left-side involvement. The mean age was 7.58±2.49 years (ranging from 3 to 12 years). The mean time since they had initial trauma was 2.42±1.28 years. The preoperative mean cubitus varus angle was 11.73±2.39°, the mean hyperextension was 13.27±2.69°, and the mean internal rotation was 36.48±5.01°. Postoperative six months' corrective mean carrying angle (valgus) was 5.79±2.46°, corrective hyperextension was 2.18±1.06°, and corrective internal rotation was 5.39±2.74°. Out of 34 cases, all had excellent results as analysed by Quick DASH and Flynn's criteria.

Conclusion: The technical modifications by K-wires in conventional modified French osteotomy provided guided compression over the osteotomy site, ensured perfect implant placement without cutting out the screw, and improved 3D (Dimensional) correction of cubitus varus deformity. So, it's safe, simple, and effective.

Keywords: Elbow deformity, Lateral closing wedge osteotomy, Paediatric

INTRODUCTION

Cubitus varus is the most common delayed malunion of supracondylar humerus fractures in children in developing countries [1,2]. The cubitus varus is a three-dimensional deformity with coronal, sagittal, and rotational components [3]. The most accepted treatment for varus malunion is corrective osteotomy using various techniques. The lateral closing wedge osteotomy by modified French technique, where a figure of eight wiring with two 3.5 mm cortical screws has been used, is a standard fixation technique [4]. Lateral closing wedge corrective osteotomy corrects coronal plane deformity (varus) and some sagittal plane deformity (extension) by taking more anterior wedge. Distal anterior and proximal posterior screw placement at osteotomies corrects the rotational deformity. The drastically reduced contact area between the osteotomy site and the SS wire during the final tightening always results in either angulation or loss of correction [5,6]. This loss of reduction intraoperatively or postoperatively has not been considered in recent literature. The novelty of present study was to concentrate on the prevention of intraoperative angulation and more stable postoperative fixation.

The patients who had undergone two surgical technical modifications with additional K-wires in a conventional modified French lateral closing wedge were analysed. First, four wires were used for precise osteotomy, followed by guided compression over the additional K-wire at osteotomy. However, it has not been patented. This study aimed to retrospectively analyse the functional outcome of cubitus varus deformity treatment with the technical modification done in Modified French Osteotomy by additional K-wires.

MATERIALS AND METHODS

The present study was a retrospective cohort study conducted at the Department of Orthopaedics, Dr. Ram Manohar Lohia Institute of Medical Sciences, Lucknow, Uttar Pradesh, India, a tertiary care 1,100 bedded multispecialty teaching hospital. The study period was from April 2019 to April 2022. The Institute's Ethics Committee (IEC) approved the study (IEC No.-66/22).

Inclusion criteria: All cubitus varus deformity patients; Age: 3-12 years; Restricted Range Of Motion (ROM) patients were also

included; Willing to give informed consent and come for follow-up/ telephonic follow-up during data collection.

Exclusion criteria: Patients with neurovascular compromise and sequelae in affected upper limb; Myositis ossificans patients; Ipsilateral other bone injuries.

This was a time bound study and the sample size was not calculated, all the patients who fulfilled the inclusion criteria in the study period were recruited for the study. Patients with cubitus varus operated in the department from (April 2019-April 2022) were identified as per records.

Thirty-four cubitus varus deformity patients were included in this study who were operated on with a lateral closing wedge-modified French osteotomy with technical modification by K-wires.

The results were analysed using Quick DASH and Flynn's criteria. The Quick DASH is scored in the disability/symptom section (11 items, 1-5) and the optional high-performance sport/music or work modules (four items, scored 1-5) [7,8]. Flynn's criteria is an accepted method for analysing functional elements, such as ROM and cosmetic elements with changes in carrying angle.

Surgical technique: Using the modified French osteotomy technique, lateral closing wedge osteotomy is the most accepted treatment for cubitus varus deformity correction [8].

The two technical modifications were made in a conventional modified French Osteotomy.

1. Four wires were used for osteotomy: proximal and distal to osteotomy. One wire is used for osteotomy guidance, and the other is for screw placement.
2. Guided uniform compression over the other additional K-wire at the osteotomy site.

The first modification ensures perfect implant placement without cutting out the screw at the osteotomy site. In the second technical modification, after correcting 3D deformity by lateral closing wedge osteotomy, one K-wire is passed from the distal to the proximal fragment in a centric lateral view. The final tightening of the SS wire done on this K-wire provides directed, uniform compression over the osteotomy site.

The benefits of this technique are: 1) It decreases the cut-out of the screw; 2) Increases the contact area over the osteotomy site; 3) During compression of SS wire, no angulation occurs.

Apart from the epidemiological data (includes total patients, age, sex, dexterous of deformity, mean age and mean time since injury), preoperative deformity, six weeks postoperative scores, three months and six months postoperative scores were collected from patient files. Patients were followed-up for six weeks because of clinical improvement and radiological union, three months for complete radiological union on basis of anteroposterior and lateral radiographs, and six months for completely normal functional limb.

STATISTICAL ANALYSIS

All data were entered into Excel sheets and tabulated. Statistical analysis of the data was done using SPSS version 21.0. Continuous data were analysed as mean±standard deviation. Categorical data were reported as numbers and percentages and analysed using the Chi-square test or Fisher's-exact test as appropriate. The value p-value <0.05 will be considered statistically significant.

RESULTS

The 34 cubitus varus deformity patients were retrospectively analysed upto six months postoperatively. The 23 (67.65%) cases were male, and 11 (32.35%) were female. The 28 (82.4%) patients were in the 5- to 10-year-old age group [Table/Fig-1]. Nearby, 20 (58.8%) of the cases involved a right-sided deformity, while the remaining 14 (41.2%) had left-side involvement. The mean age was 7.58±2.49 years (ranging from 3 to 12 years). The mean time since

they had initial trauma was 2.42±1.28 years. The preoperative mean cubitus varus angle was 11.73±2.39, the mean hyperextension was 13.27±2.69, and the mean internal rotation was 36.48±5.01. Postoperative six months' corrective mean carrying angle (valgus) was 5.79±2.46, corrective hyperextension was 2.18±1.06, and corrective internal rotation was 5.39±2.74 [Table/Fig-2].

Variables	N (%)
Age distribution (Years)	
3-5	8 (23.5)
6-8	11 (32.35)
9-12	15 (44.15)
Mean±SD	7.58±2.49
Gender	
Female	11 (32.35)
Male	23 (67.65)
Time since initial injury (years)	
Mean±SD	2.42±1.28

[Table/Fig-1]: Demographic parameter.

The radiological union at the osteotomy site occurred over a mean period of 6.3 weeks. All 34 cases achieved excellent results per Flynn's criteria and Quick DASH scoring system [Table/Fig-3-5]. All patients achieved their routine activity within six months of the postoperative period. The Baumann's angle was corrected from a mean preoperative 96.73±2.39° to a mean six months postoperative 79.18±2.50°. Of the 34 patients, the Quick DASH preoperative mean was 67.64±4.48, the postoperative mean six weeks was 57.03±3.01, and the postoperative mean six months was 77.76±4.36. In comparison, none showed fair or poor results in the follow-up. There was a superficial pin tract infection in two cases, but it responded to local wound care and antibiotics. Out of 34 cases, all had excellent to good results as analysed by Quick DASH and Flynn's criteria; none had reported pin loosening, gross loss of fixation, or loss of correction. Cosmetically, all were satisfied with the outcome [Table/Fig-6-8]. There was no neurovascular complication, unsightly scar, or residual deformity. Most of the patients regained their preinjury functional status in the three months postoperatively with excellent cosmetic correction.

Variables	Preoperative (Angle) (Mean±SD) (°)	Postoperative (Angle at six months) (Mean±SD) (°)	p-value
Hyperextension	13.27±2.69	2.18±1.06	t=22.03 p<0.0001*
Baumanns angle	96.73±2.39	79.18±2.50	t=29.15 p<0.0001*
Internal rotation deformity	36.48±5.01	5.39±2.74	t=31.28 p<0.0001*
Carrying angle	11.79±2.39	5.79±2.46	t=10.05 p<0.0001*

[Table/Fig-2]: Preoperative and postoperative clinical parameter.

*A p-value <0.05 was considered to be statistically significant

	Preoperative (mean±SD)	At 6 weeks (mean±SD)	At 6 months (mean±SD)	p-value
Quick DASH criteria	67.64±4.48	57.03±3.01	77.76±4.36	F=221.0 p<0.0001*

[Table/Fig-3]: Quick DASH criteria.

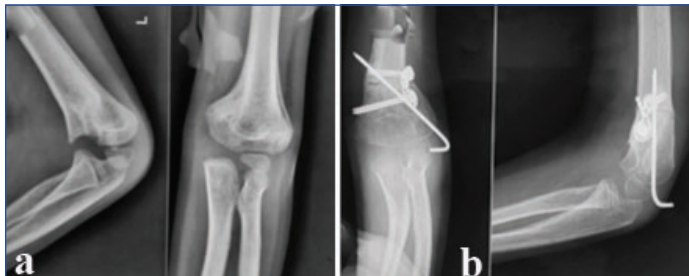*A p-value <0.05 was considered to be statistically significant

Results	Rating	Cosmetic factor: Carrying angle (°)	Functional factor: Motion loss (°)
Satisfactory	Excellent	0-5	0-5
	Good	>5-10	>5-10
	Fair	>10-15	>10-15
Unsatisfactory	Poor	>15	>15

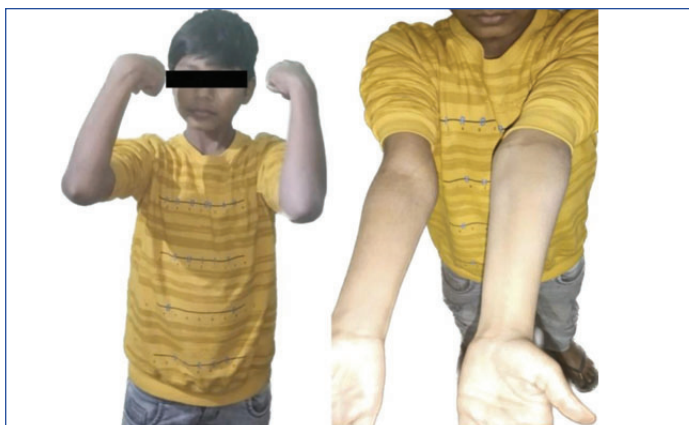[Table/Fig-4]: Flynn's criteria [8].

Flynn's Criteria Scoring	Preoperative		At 6 months		p-value
	N	%	N	%	
Fair	21	61.76	0	0	$\chi^2=66.00$ $p<0.0001^*$
Good	8	23.5	0	0	
Poor	5	14.7	0	0	
Excellent	0	0	34	100.00	

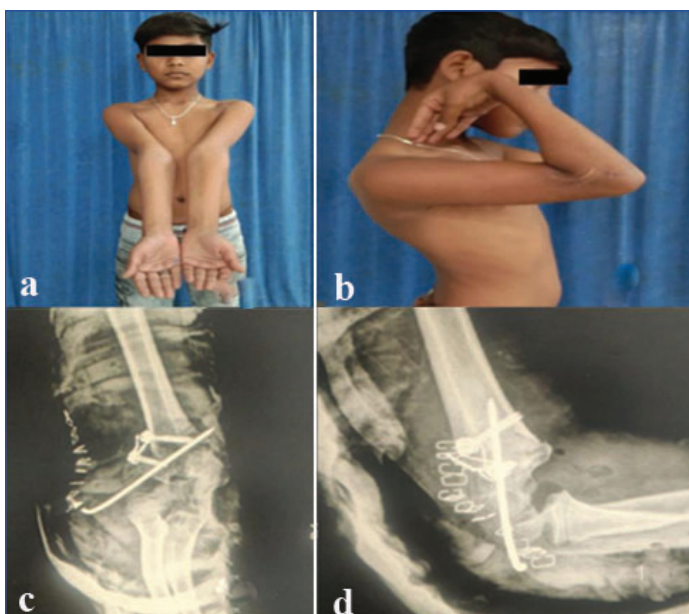
[Table/Fig-5]: Flynn's Criteria Scoring. Chi-Square test was applied



[Table/Fig-6]: (a) Radiograph showing preoperative varus angulation. (b) Postoperative six months radiograph showing complete correction of deformity and union at the osteotomy site.



[Table/Fig-7]: Postoperative clinical photograph of near normal carrying angle and full Range Of Motion (ROM).



[Table/Fig-8]: (a,b) Postoperative clinical photograph of near normal carrying angle and the full Range Of Motion (ROM); (c,d) Postoperative 6-week radiograph showing complete deformity correction.

DISCUSSION

The distal humeral osteotomy of cubitus varus is a technically demanding procedure with a high complication rate. Solfelt DA et al., reviewed the surgical outcome of cubitus varus deformity after four distal humerus osteotomy techniques: 1) Lateral closing wedge;

2) dome; 3) step-cut translational; 4) distraction osteogenesis. Each osteotomy and fixation technique has advantages and disadvantages; no procedure is statistically safer [6,8]. They analysed 894 patients in 40 studies, with an overall good to excellent result of 87.8% [8].

Raney EM et al., analysed 68 patients with distal humerus osteotomy. They found 23 (34%) patients had clinically remarkable complication rates in the form of loss of reduction loss of flexion, transient nerve palsy, lateral prominence, scar, and delayed union [9]. Lateral close wedge osteotomy of the distal humerus is the easiest, safest correction method for complex cubitus varus deformity. The type of osteotomy fixation is always a concern to achieve good to excellent results [8]. Various fixation methods include using two screws and a figure of eight tension band wire, plate fixation, cross K-wire fixation, or no fixation [9,10]. Modifying lateral closed wedge osteotomy for the cubitus varus deformity has certain advantages. The benefits are that it decreases the cut out of the screw, increases contact area over the osteotomy site, and prevents angulation at the osteotomy site during compression of SS wire. Additional K-wires and two screws with tension band wiring were used at the osteotomy. Final tightening of SS wire is done on this K-wire which provides directed uniform compression over the osteotomy site. This fixation method has given good to excellent results in deformity correction in the study. The medial side periosteum over the osteotomy site has not been stripped, providing us with the biological environment for healing. An appropriate anterior wedge was removed before the osteotomy's fixation in hyperextension deformity. Su Y and Nan G, recommended the isosceles triangular osteotomy, which left the medial cortex intact, and fixation was performed using two lateral 2 mm K-wires wires; one patient fell, displacing the osteotomy, and needed revision of the fixation [11]. Srivastava AK et al., managed cubitus varus with lateral closed wedge osteotomy, fixed by two screws with a figure-eight tension band wire with additional K-wire, and had a good result in all cases; only two cases had superficial pin tract infection, and one case had lateral condylar prominence [12]. The additional K-wire used by Srivastava AK et al., was only for stability. In present retrospective study, no loss of correction occurred with the technical modification of K-wires. Kasirajan S et al., used a reconfigured locking plate for fixation of the osteotomy because, according to their study, fixation of the osteotomy with figure-eight wiring or 3.5 mm cortical screws were insufficient to hold the distal fragment in children above the age of eight years [13]. The present study was conducted, using fixation of osteotomies with a figure-eight wire and 3.5 mm cortical screws with additional K-wires intraoperatively, achieved correction that was not lost until the union was achieved. According to Tanwar YS et al., the radiological union took 5.5 weeks, and the mean correction at osteotomy was 27° [14]. The radiological union at the osteotomy site in present study took over a mean period of 6.3 weeks. Jain AK et al., performed lateral closing wedge osteotomies in 25 children with cubitus varus deformity managed by modified French osteotomies with tension band wiring; five children have lost some correction [15]. According to Orbach H et al., the mean preoperative carrying angle was -20.25°, and the postoperative mean carrying angle was 9.7° [16]. In the present study, the six-month postoperative mean carrying angle was 5.79°. North D et al., retrospectively reviewed 90 children with cubitus varus treated by French osteotomy; 93.3% of children had a good result. The complications were lateral condyle prominence in one child, residual varus, and more than 20° of preoperative ROM loss. The remodeling of hyperextension deformity (10°), Lateral Condyle Prominent Index (LCPI) 12 years, and internal rotation deformity were well tolerated [17]. Verka PS et al., managed cubitus varus deformity in children by closed dome osteotomy and had good to excellent results per present study [18]. If a further long-term prospective study is done, it will directly benefit patients and

orthopaedic surgeons and form the basis for the recommendation of a cubitus varus deformity correction standard operating protocol.

Limitation(s)

Since this was a time bound study, sample size was not calculated statistically.

CONCLUSION(S)

The technical modifications by additional K-wires in conventional modified French osteotomy provided guided compression over the osteotomy site, ensured perfect implant placement without cutting out the screw, and improved 3D correction of cubitus varus deformity. Postoperatively, children have fewer complications, near normal elbow movement, a smaller postoperative scar, and was cosmetically more acceptable.

REFERENCES

- [1] Farnsworth CL, Silva PD, Mubarak SJ. Etiology of supracondylar humerus fractures. *J Pediatr Orthop*. 1998;18(1):38-42.
- [2] Marquis CP, Cheung G, Dwyer JSM, Emery DFG. Supracondylar fractures of the humerus. *Curr Orthop*. 2008;22:62-69.
- [3] Abzug JM, Herman MJ. Management of supracondylar humerus fractures in children: Current concepts. *J Am Acad Orthop Surg*. 2012;20(2):69-77.
- [4] Davids JR, Maguire MF, Mubarak SJ, Wenger DR. Lateral condylar fracture of the humerus following posttraumatic cubitus varus. *J Pediatr Orthop*. 1994;14(4):466-70.
- [5] Bauer AS, Pham B, Lattanza LL. Surgical correction of cubitus varus. *J Hand Surg Am*. 2016;41(3):447-52.
- [6] Yamamoto I, Ishii S, Usue M. Cubitus varus deformity following supracondylar fracture of the humerus. A method for measuring rotational deformity. *Clin Orthop Relat Res*. 1985;201:179-85.
- [7] Gabel CP, Yelland M, Melloh M, Burkett B. A modified QuickDASH-9 provides a valid outcome instrument for upper limb function. *BMC Musculoskelet Disord*. 2009;10:161.
- [8] Solfelt DA, Hill BW, Anderson CP, Cole PA. Supracondylar osteotomy for the treatment of cubitus varus in children: A systematic review. *Bone Joint J*. 2014;96-B(5):691-700.
- [9] Raney EM, Thielen Z, Gregory S, Sobralaske M. Complications of supracondylar osteotomies for cubitus varus. *J Pediatr Orthop*. 2012;32(3):232-40.
- [10] Kim HT, Lee JS, Yoo CI. Management of cubitus varus and valgus. *J Bone Joint Surg Am*. 2005;87(4):771-80.
- [11] Su Y, Nan G. Lateral closing isosceles triangular osteotomy for the treatment of a post-traumatic cubitus varus deformity in children. *Bone Joint J*. 2016;98-B(11):1521-25.
- [12] Srivastava AK, Srivastava D, Gaur S. Lateral closed wedge osteotomy for cubitus varus deformity. *Indian J Orthop*. 2008;42(4):466-70.
- [13] Kasirajan S, Govindasamy R, Lokayah SK. Functional outcome of modified French osteotomy fixed with recon-locking compression plate in older children. *J Clin Orthop Trauma*. 2021;16:202-07.
- [14] Tanwar YS, Habib M, Jaiswal A, Singh S, Arya RK, Sinha S. Triple modified French osteotomy: A possible answer to cubitus varus deformity. A technical note. *J Shoulder Elbow Surg*. 2014;23(11):1612-17.
- [15] Jain AK, Dhammi IK, Arora A, Singh MP, Luthra JS. Cubitus varus: Problem and solution. *Arch Orthop Trauma Surg*. 2000;120(7-8):420-25.
- [16] Orbach H, Rozen N, Rubin G, Dujovny E, Bor N. Outcomes of French's corrective osteotomy of the humerus for cubitus varus deformity in children. *Isr Med Assoc J*. 2018;20(7):442-45.
- [17] North D, Held M, Dix-Peek S, Hoffman EB. French osteotomy for cubitus varus in children: A long-term study over 27 years. *J Pediatr Orthop*. 2016;36(1):19-24.
- [18] Verka PS, Kejariwal U, Singh B. Management of cubitus varus deformity in children by closed dome osteotomy. *J Clin Diagn Res*. 2017;11(3):RC08-RC12.

PARTICULARS OF CONTRIBUTORS:

1. Assistant Professor, Department of Orthopaedics, Dr. Ram Manohar Lohia Institute of Medical Sciences, Lucknow, Uttar Pradesh, India.
2. Associate Professor, Department of Orthopaedics, Dr. Ram Manohar Lohia Institute of Medical Sciences, Lucknow, Uttar Pradesh, India.
3. Professor, Department of Orthopaedics, Dr. Ram Manohar Lohia Institute of Medical Sciences, Lucknow, Uttar Pradesh, India.
4. Associate Professor, Department of Orthopaedics, Dr. Ram Manohar Lohia Institute of Medical Sciences, Lucknow, Uttar Pradesh, India.
5. Professor, Department of Orthopaedics, Dr. Ram Manohar Lohia Institute of Medical Sciences, Lucknow, Uttar Pradesh, India.
6. Associate Professor, Department of Orthopaedics, Dr. Ram Manohar Lohia Institute of Medical Sciences, Lucknow, Uttar Pradesh, India.
7. Assistant Professor, Department of Orthopaedics, Dr. Ram Manohar Lohia Institute of Medical Sciences, Lucknow, Uttar Pradesh, India.

NAME, ADDRESS, E-MAIL ID OF THE CORRESPONDING AUTHOR:

Dr. Pankaj Aggarwal,
Associate Professor, Department of Orthopaedics, Dr. Ram Manohar Lohia Institute of Medical Sciences, Vibhuti Khand, Gomti Nagar, Lucknow-226010, Uttar Pradesh, India.
E-mail: pankaj.doc@gmail.com

AUTHOR DECLARATION:

- Financial or Other Competing Interests: None
- Was Ethics Committee Approval obtained for this study? Yes
- Was informed consent obtained from the subjects involved in the study? Yes
- For any images presented appropriate consent has been obtained from the subjects. Yes

PLAGIARISM CHECKING METHODS: [Jain H et al.]

- Plagiarism X-checker: Feb 06, 2023
- Manual Googling: May 20, 2023
- iThenticate Software: May 24, 2023 (16%)

ETYMOLOGY: Author Origin

EMENDATIONS: 7

Date of Submission: **Feb 03, 2023**

Date of Peer Review: **Mar 04, 2023**

Date of Acceptance: **May 26, 2023**

Date of Publishing: **Jul 01, 2023**