



## **A Recent Experience in an Egyptian Medical Center: Strategies for the Clinical and Genetic Diagnoses of Nephropathic Cystinosis**

**Mohammad Al-Haggar<sup>1\*</sup>, Anna Taranta<sup>2</sup>, Paola Bencivenga<sup>2</sup>,  
Nermin Ahmad<sup>3</sup>, Hany Abo Hadid<sup>4</sup> and Yahya Wahba<sup>1</sup>**

<sup>1</sup>*Department of Pediatrics, Genetics Unit, Mansoura University Children's Hospital, Mansoura, Egypt.*

<sup>2</sup>*Department of Nephrology and Urology, Division of Nephrology, Bambino Gesù Children's Hospital, IRCCS, Rome, Italy.*

<sup>3</sup>*Department of Diagnostic Radiology, Mansoura University Children's Hospital, Mansoura, Egypt.*

<sup>4</sup>*Department of Pediatrics, Cardiology Unit, Mansoura University Children's Hospital, Mansoura, Egypt.*

### **Authors' contributions**

*This work was carried out in collaboration between all authors. Author MA carried out the clinical diagnosis, pedigree construction and study design, prepared the manuscript draft.*

*Author AT carried the molecular genetic studies and revised the manuscript. Author PB carried the in silico studies. Author NA arranged the imaging studies for the eye and heart anomalies. Author HAH made the echocardiographic evaluation and follow up of heart malformations. Author YW carried the biochemical analyses and arranged for molecular analyses. All authors read and approved the final manuscript.*

**Research Article**

**Received 27<sup>th</sup> April 2013**  
**Accepted 27<sup>th</sup> May 2013**  
**Published 17<sup>th</sup> June 2013**

### **ABSTRACT**

**Aims:** To screen cases of infantile cystinosis among different forms of proximal renal tubular acidosis (RTA).

**Study Design:** Cross sectional.

**Place and Duration of Study:** From a total of 25 families of RTA followed up in Nephrology unit of Mansoura University Children's Hospital (MUCH), Egypt, two unrelated families were diagnosed as infantile nephropathic cystinosis using clinical suspicion plus mutation analysis of CTNS gene in the period between January 2008 and

\*Corresponding author: Email: [m.alhaggar@yahoo.co.uk](mailto:m.alhaggar@yahoo.co.uk);

November 2012.

**Methodology:** Two families with multiple cases of infantile nephropathic cystinosis have been diagnosed. In absence of high-performance liquid chromatography and tandem mass spectrometry used for measuring intraleucocyte cystine, diagnostic tools for cystinosis used in the current work were clinical and laboratory evidences of PRTA, slit lamp detection of corneal cystine crystals and finally identification of *CTNS* gene mutations. All patients were subjected to routine echocardiography because of accidental discovery of heart malformation in one case. Rare mutant variant of the first family was subjected to RNA analysis which unfortunately failed, alternatively an in silico study was used to predict splice site.

**Results:** All patients with cystinosis manifested a severe clinical course. Proband of family 1 showed two known mutations; deletion in the exon 3 (c.18\_21 del GACT) and substitution in acceptor splice site of intron 11 (c.971 -12G>A). In silico study predicted an anticipated splice site that modified the open reading frame in carboxy-terminal region. Probands of family 2 were affected by ventricular and atrial septal defects in younger, and mild mitral and aortic incompetence in older patient; their DNA analysis revealed a novel nonsense mutation (c.734 G>A) which caused a premature stop codon in position 245 of protein.

**Conclusion:** Nephropathic cystinosis has been diagnosed with ease in Egyptian population without need of sophisticated investigations. A novel mutation had been added to the list of *CTNS* gene variants.

*Keywords: Cystinosis; CTNS gene; truncating mutation; cardiac manifestation.*

## 1. INTRODUCTION

Cystinosis is an autosomal recessive disorder characterized by an intralysosomal accumulation of the amino acid cystine in many organs of the body, due to the defective transport activity of the lysosomal transmembrane protein, cystinosin. In 1998, Town et al. mapped the gene responsible for cystinosis (*CTNS*) on the short arm of chromosome 17 (p13), described the genomic structure composed of 12 exons, 10 of which (from 3<sup>rd</sup> to 12<sup>th</sup>) were codifying, and found mutations, including deletions, insertions and substitutions in *CTNS* gene in patients with cystinosis [1]. Since then, many different variants have been described in European and American patients [2-4]. The most common mutation in North Europe and America is a large 65 kb deletion that removes the 3-10 exons [5]. Over the last few years, nephropathic cystinosis study has been extended to Middle East population, describing novel mutations of the *CTNS* gene [6-8].

Cystinosis has been classified into three clinical forms on the basis of age at the onset and symptom severity: 1) infantile (OMIM #219800), the most frequent and severe form; 2) juvenile (OMIM #219900), characterized by late-onset and mild renal tubulopathy; 3) adult (OMIM #219750) with non-nephropathic, but purely ocular manifestation. All three forms of the disease are inherited in recessive pattern [9].

Cystinosis accounts for 5% of chronic childhood renal failure [10]. Infantile nephropathic cystinosis manifests itself with renal tubular Fanconi syndrome (RTA) within the first year of life. Progressive renal damage results in urinary loss of water, sodium, potassium, bicarbonate, calcium, magnesium, phosphates, amino acids, glucose, proteins, and many other solutes reabsorbed in the renal tubules [9,11]. Full-blown Fanconi syndrome is characterized by polyuria, thirst, failure to thrive, vomiting, periods of dehydration,

constipation, developmental delay, metabolic acidosis and rickets in some patients with hypokalemia and hypophosphatemia [12]. In most patients, the glomerular filtration rate (GFR) remains in the normal range up to 2 years of age, then renal function progressively deteriorates to end-stage renal disease (ESRD) at the end of the first decade of life in the absence of treatment with cysteamine [13].

Young patients with infantile cystinosis usually develop extra-renal symptoms due to cystine accumulation in organs such as eyes, liver, thyroid, pancreas, muscle, gonads and nervous system. Cystine deposits in the eyes cause painful corneal erosions, peripheral corneal neo-vascularization, punctate, filamentous or band keratopathy, iris crystals, and retinal degeneration [14]. Moreover, impairments in endocrine glands are responsible for hypothyroidism, insulin dependent diabetes mellitus and hypogonadism. Cystinosis could be accompanied by encephalopathy, stroke-like episodes, benign intracranial hypertension and myopathy [9].

Diagnosis of cystinosis is suspected in all patients with failure to thrive with symptoms and signs of renal Fanconi syndrome. Index of suspicion is usually increased within the first year of life by the observation of cystine crystals in cornea which is quite pathognomonic. Definitive diagnosis of cystinosis is achieved by the detection of elevated intracellular cystine content in polymorphonuclear leukocyte cells using high performance liquid chromatography (HPLC) or tandem mass spectrometry (MS/MS) [15,16]. Moreover, genetic analysis also confirms the clinical diagnosis. However in our institute, nephrologists preferred to start cysteamine without delay based only on failure to thrive, Fanconi-symptoms and signs plus corneal crystals.

Cystinosis affects 1: 200,000 newborns in Europe and United States. Since 1983, non-profit organizations have been founded by patients' families to provide services and information on the disease. The foundation activities in association with the medical community have promoted scientific research and encouraged the generation of new centers. Thanks to these working strategies, the foundations have disclosed the knowledge of cystinosis in different countries such as South America (Brazil, Mexico), Australia and South Africa. Recently, novel cases of cystinosis have also been described in the Middle or Far East populations; namely Oman, Turkey and Thailand [6-8].

The collaboration between the Nephrology unit of Mansoura University Children's Hospital (MUCH), Egypt, which has followed up 25 families with unclassified RTA and Institute Research of Bambino Gesù Children's Hospital, Rome, Italy which has performed genetic analysis on two families with suspected cases of infantile cystinosis, had allowed the confirmation of diagnosis of cystinosis without the necessity of sophisticated investigations (HPLC and MS/MS) which were not readily available in Egypt. Moreover, description of *CTNS* gene variants in Egyptian patients had been made for the first time.

## **2. MATERIALS AND METHODS**

Among the 25 Egyptian families with documented unclassified RTA, regularly followed up at the Nephrology Clinic, Mansoura University Children's Hospital (MUCH), two unrelated Egyptian families with positive consanguinity had been screened over 4 years (2008 - 2012). Each family showed more members under suspicion of cystinosis because of intense photophobia and RTA symptoms. Confirmation of cystinosis diagnosis had been performed by slit lamp examination and the repeated laboratory check (urinalysis, renal function tests, fasting and postprandial blood sugar, serum calcium, phosphorus, alkaline phosphatase,

sodium and potassium, and arterial blood gas analysis including anion gap; initial laboratory parameters at time of validation of diagnosis is shown in Table 1). As the biochemical methods for measurement of intraleucocyte cystine content (HPLC and MS/MS) are not readily available in most Egyptian centers, molecular analysis of *CTNS* gene for all members had been arranged in collaboration with Bambino Gesù Children's Hospital and Research Institute of Rome (Italy) to confirm cystinosis diagnosis.

**Table 1. Initial laboratory parameters of probands at time of validation of diagnosis**

Test (serum)	Family 1	Family 2		Reference range
	3203	4201	4202	
Sodium (mmol/L)	135	128	136	135-145
Potassium (mmol/L)	3	2.5	3.1	3.5-5.5
Chloride (mmol/L)	112	109	115	98-107
Bicarbonate (mmol/L)	16	12	14	22-29
Creatinine (mg/dl)	0.6	3.4	0.6	0.5-0.9
Total calcium (mmol/L)	2.42	2.20	2.45	2.1-2.55
Corrected calcium (mmol/L)	0.64	0.60	0.7	2.1-2.55
Phosphate (mmol/L)	0.58	0.62	0.7	1.1-2.1
Alkaline phosphatase (units/L)	841	1120	400	0-281
Albumin (g/dL)	3.8	3.1	3.9	3.5-5
Parathyroid hormone (pmol/L)	2.5	7.9	2.5	1.6-9.3

A written informed consent has been received from parents of patients before enrolling them in the study.

### 2.1 Mutation Analysis

Genomic DNA was extracted from peripheral blood mononuclear cells of all available Egyptian family members, using the DNA purification Capture Column Kit (QIAGEN, Milan, Italy). All coding and flanking intronic regions of *CTNS* gene were amplified by polymerase chain reaction (PCR). Direct sequencing of PCR products was performed with dye terminator cycle sequencing quick start kit (Beckman Coulter, Brea, CA, USA) and analyzed with CEQ2000XL DNA Analysis System (Beckman Coulter).

### 2.2 RNA Analysis

It had been done for the rare mutant variant that was described in the first family (family1) to test for its pathogenicity, unfortunately because of the RNA damage due to technical and logistic reasons during its transfer from Egyptian to Italian laboratory. Alternatively *in silico* analysis had been arranged.

### 2.3 In Silico Analysis

It was used for the detection of splice alterations using NetGene2 program ([www.cbs.dtu.dk/services/NetGene2/](http://www.cbs.dtu.dk/services/NetGene2/)).

## 2.4 Echocardiographic Evaluation of Probands of Family 2

Doppler studies had been done because of the accidental discovery of cardiac murmur in younger patient.

## 3. RESULTS

### 3.1. Case Presentations

#### 3.1.1 Family 1

A 2 years old female child (3203) was the fourth child, born full term from consanguineous parents (Fig. 1a). She had an older sibling died at 7.5 years of age by renal failure of unknown cause. All proband's growth and developmental parameters were normal at 9 months of life despite of adequate nutritional history. Patient showed clinical signs of rickets with no deformities or organomegaly. X-ray of wrists showed reduced bone density with delayed bone age, widened metaphysis with cupping and fraying of radius and ulna. Routine urinalysis as well as its aminogram using HPLC showed laboratory evidence of RTA (Table: 1). Ultrasound abdomen including kidneys was unremarkable. Ophthalmic examination revealed normal visual acuity, no strabismus or nystagmus but with slit lamp examination there were fine, shiny crystal-like deposits diffusely distributed in the corneal epithelium and stroma. Diagnosis of cystinosis was based on the ophthalmic detection of corneal crystals in conjunction with Fanconi-like RTA, however the sophisticated measurement of intracellular cystine level had not been readily available. Affected child (3203) was kept on supportive treatment to correct the metabolic acidosis and hypokalemia (large amounts of alkali 10-15 mEq/Kg/day, in the form of Polycitra that contain part of bicarbonate as potassium citrate and phosphates), and active vitamin D (Alpha calcitriol, in a dose of 0.04 ug/m<sup>2</sup>/day), oral calcium therapy was given as an adjuvant therapy. Cysteamine bitartrate (Cystagon), capsules in a dose of 1.30 grams/m<sup>2</sup>/day, was started with 1/4 the recommended dose then increased gradually over a period of 4-6 weeks to avoid intolerance. Treatment was started at the age of 2 but was not strictly regular. On follow up, at 6.5 years of age, serum creatinine starts to increase (3 mg/dl) with progressive drop of GFR (50 ml/min/m<sup>2</sup> surface area). Follow up renal ultrasound revealed increased echogenicity.

#### 3.1.2 Family 2

A 6-month old Egyptian female infant (4202), the third born to a remote consanguineous couple (Fig. 2a). Family history was positive for similar condition in her older sister (died at 11 years of age because of pulmonary edema possibly as a sequence of ESRD), who had been maintained on dialysis for 7 months before death. Cystinosis had been suggested for the two alive probands (4201, 4202; 9 and 7-years respectively) based on ophthalmoscopic examination and laboratory finding of proximal RTA (Table 1). The two probands suffered from severe photophobia and excessive lacrimation on exposure to daylight since at 1 year of age, they are currently subjected for thorough ophthalmologic examination; slit examination confirmed the presence of cystine crystals in both cases, however posterior segment examination revealed retinal pigmentary changes with epithelial mottling in the older proband (4201). The two patients had been maintained on cysteamine, but since the treatment started at earlier age and follow up was relatively strict in case 4202 compared to her older sib (4201), control of eye symptoms and preservation of renal function was noticed

in 4202, however renal failure supervened in 4201 at the age of 8 (GFR = 42 ml/min/m<sup>2</sup> surface area).

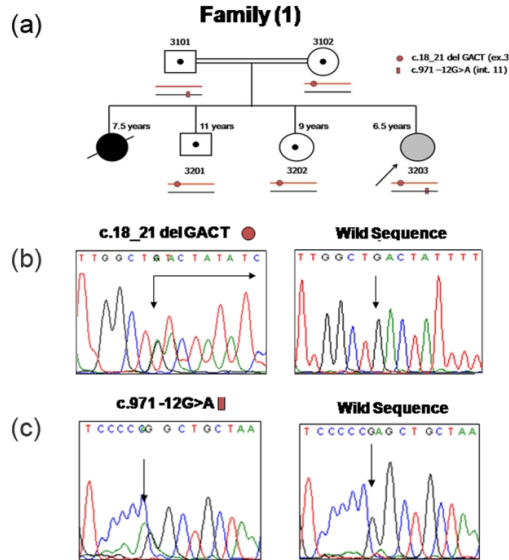


Fig. 1. (a) Family 1 pedigree showing positive consanguinity and a compound heterozygous proband. Electropherograms showing mutations of CTNS gene in the family 1. (b) The first mutation assigned by circle is a 4-bp deletion in exon 3 (c.18\_21 del GACT). (c) The second mutation assigned by rectangle is a splicing variant in intron 11 (c.971 -12G>A)

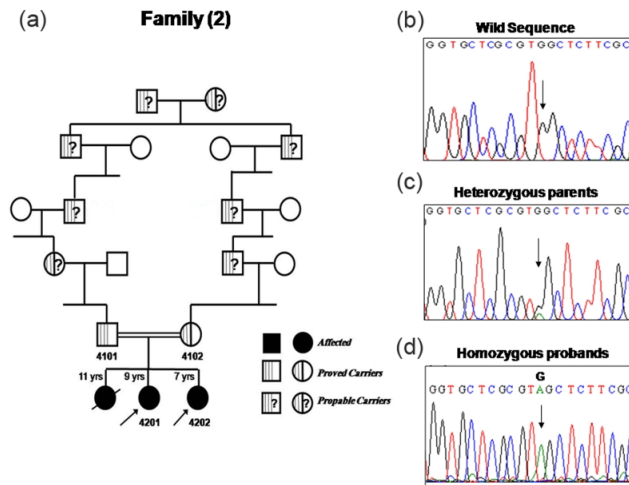
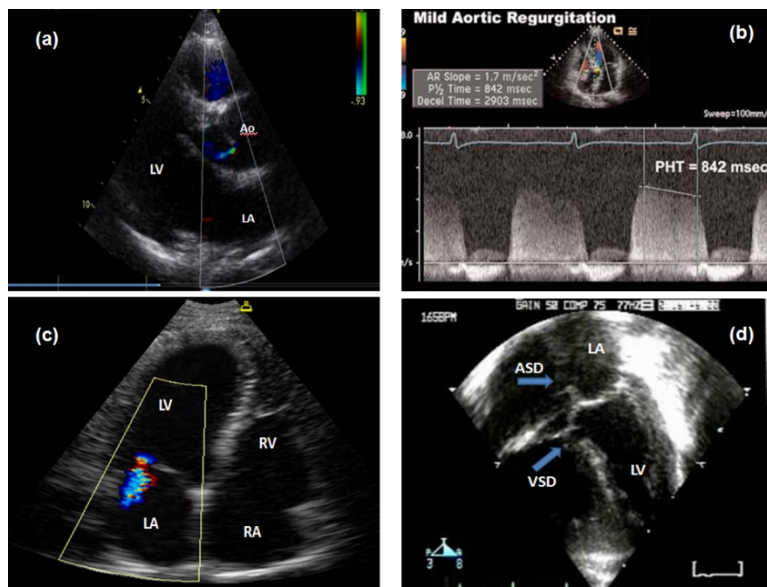


Fig. 2. (a) Family 2 pedigree showing remote consanguinity, heterozygous parents (4101, 4102) and homozygous probands (4201, 4202). Electropherograms showing control sequence (b), a novel nonsense mutation (c.734 G>A) in the heterozygous (c) and homozygous (d) forms. G>A substitution at position 734 of coding region causes tryptophan substitution to stop codon (TAG), at amino acid position 245 of protein (p.W245X)

Cardiac examination for case 4202 revealed pansystolic murmur maximum over the left parasternal border propagating all over the precordium, echocardiography confirmed the presence of both ventricular and atrial septal defects (2-dimensional mode; Fig. 3d). Echocardiography for case 4201 revealed a mild degree of mitral and aortic incompetence although she was asymptomatic and cardiac auscultation was uneventful (Doppler studies; Fig. 3a, b, and c).

Patients' growth curves were linear; weight was 25<sup>th</sup> - 50<sup>th</sup> percentile and height was 50<sup>th</sup> percentile with the adequate supportive treatment mentioned above in case of family 1 including active vitamin D and high protein diet. Social development was also appropriate for age. Older proband 4201 developed ESRD and was maintained on peritoneal dialysis for 5 months however the younger one 4202 still had normal renal function.



**Fig. 3. Echocardiographic findings in patients of family 2; (a) Color flow Doppler showing trivial aortic incompetence (LV=left ventricle, LA=left atrium, Ao= aorta), (b) Continuous wave (CW) Doppler study showing aortic regurgitation (AR) slope = 1.7 m/sec, pressure half time (PHT) = 842 m.sec (AR is considered mild if PHT > 500 m.sec), (c) Color flow Doppler showing grade I mitral regurgitation, mild thickened mitral valve leaflets, mild LV dilatation (RV = right ventricle, RA = right atrium), (d) Two-dimensional mode echo showing secundum atrial septal defect (ASD) measured 5.5 mm, and inlet ventricular septal defect (VSD) measured 4 mm**

### 3.2 Sequence Analysis of the CTNS Gene

#### 3.2.1 Family 1

Proband was heterozygous for two known mutations: c.18\_21del and c.971-12G>A [1, 3]. Briefly, the first mutation was a deletion of four nucleotides (GACT) in the exon 3 resulting in a frame shift with a sequence change at protein level. The predicted cystinosis showed a threonine substitution to phenylalanine at amino acid 7 and an anticipated stop codon that lead to a shorter protein, long only 13 amino acids (p.T7fsX7). The second mutation was a

substitution G>A in the acceptor splice site of the exon 12. An *in silico* analysis of the sequence with the mutation c.971–12 G>A predicted a highly confident splice site (confidence 0.85), anticipated 10 nucleotides upstream of starting exon 12. This variant should modify the open reading frame from codon 323 introducing 44 different amino acids in the carboxy-terminal region of the protein. Proband's siblings and mother were heterozygous for the deletion (Fig. 1b) while the father was heterozygous for splicing mutation (Fig. 1c).

### **3.2.2 Family 2**

Probands were homozygous for a novel nonsense mutation characterized by G>A substitution in the exon 10, at position 734 of *CTNS* gene (c.734 G>A). This mutation introduced a stop codon at position 245 of cystinosin (p.W245X) that lead to shorter protein lacking of 122 amino acids composing the last three loops of the protein (Fig. 2d). Parents who were remote consanguineous (Fig. 2a) showed a heterozygous trait (Fig. 2c), when compared to wild-type sequence of this DNA stretch (Fig. 2b).

## **4. DISCUSSION**

Although cystinosis is a rare disease with only 2,000 cases described in the world, the number of patients could be underestimated because of the inappropriate knowledge of the disorder in the emerging countries. For this reason, foundation activities provide an important contribution in the awareness of the disease in the medical community. This study is born from the collaboration between the Egyptian medical center which started to follow up patients with cystinosis since 2008 and the Italian research group which has performed research projects funded by the Cystinosis Research Foundation and the Cystinosis Research Network.

Cystinosis appears to be a monogenic disease caused by variants of *CTNS* gene. Initially, hypothesis that other genes were responsible for cystinosis was due to the failed detection of mutations on *CTNS* gene in French (6%), American (19%) and Italian (18%) patients with assured diagnosis of cystinosis [2,4,17]. Subsequently, deeper studies on DNA or mRNA of some genetically unclassified patients have revealed mutations in unexpected regions such as lariat branch point or intronic duplication that modified the splicing site [3,18].

To date, more than 100 variants causing cystinosis have been identified worldwide. This evidence has allowed the knowledge of the allelic frequency of more mutations in different populations. As demonstrated, the most common mutation is a 65 kb deletion that removes the first 10 exons of the *CTNS* gene. This deletion which has a German origin, has migrated in the British Isles and subsequently in America [2]. The deletion frequency is strongly decreased in the populations of Mediterranean area such as Italy or is absent in Turkish and Arabic people [4,7]. Although we have only analyzed three Egyptian patients with cystinosis, the lack of 65 kb deletion has been confirmed. Studying the variants found in Egyptian patients, the known c.18\_21 deletion GACT appears to be a recurrent mutation with an allele frequency of approximately 6% in various populations of North America and Europe. Recently, the deletion has also been described in cystinotic patients of North and Middle East [6,7]. Moreover, the concurrent mutations c.18\_21del and c.971 –12G>A found in Egyptian patient, has also been described in a Thai patient [8]. This suggests a high frequency of the variant c.18\_21 in Middle East population. On the basis of data supplied by papers, the rare variant c.971 –12G>A has been identified in only two patients in the world, but its capacity of causing a splicing error has not demonstrated [3,8]. In analyzing this rare



mutant form in proband of family 1, because of the degradation of patient's mRNA we have performed an *in silico* analysis and predicted an altered *CTNS* mRNA sequence that should be translated into nonfunctional protein.

All the three cystinotic patients of the two unrelated Egyptian families run a severe clinical course as demonstrated by renal failure and even death between 7.5-11 years of age in at least one member in each family. Probands of family 2 have a novel nonsense mutation (p.W245X) which causes loss of the last three loops of the protein. This homozygous mutation is responsible for severe clinical course characterized by death in the first offspring (non-tested), early onset of renal failure in case 4201, and eye involvement despite the early regular use of cystine chelating agent in case 4202. Moreover, the probands 4201 and 4202 manifested unique cardiac involvements despite the different anatomic nature (left sided valvular incompetence in case 4201 and septal defects in case 4202). We speculate that pulmonary edema reported to be the cause of death of the oldest non-tested sibling could be a sign of hidden left sided congenital heart disease.

In literature, cardiovascular complication in patients with cystinosis had been related to the relative longevity of patients ranging from arterial stiffness and vascular atheroma formation, which is due to the cystine accumulation in the wall of blood vessels, to different forms of cardiomyopathy. Adequate cysteamine treatment reduces the risk of vascular involvement even far below the risk of chronic kidney disease of different causes [19]. Two cases of cardiomyopathy have been diagnosed in young adult females with nephropathic cystinosis; the first one who had been documented in a Caucasian pregnant female receiving haemodialysis manifested dilated cardiomyopathy. Although this patient stopped cysteamine during pregnancy, authors argued against cystinosis being the cause but rather suggested the case to be a simple pregnancy-associated cardiomyopathy [20]. The second woman had been diagnosed with an isolated left ventricular non-compaction at the age of 24; she showed reduced exercise tolerance due to left ventricular dysfunction [21]. The above cited cases were quite different regarding nature and age of onset of the cardiovascular manifestations in comparison to patients described in our current report. Knowing the relative high frequency of congenital heart malformations in general population, it is very early to consider cardiac malformations in our cases to be closely related to this novel mutation as a cause and an effect, alternatively the possibility of other interacting genes should be probable.

## 5. CONCLUSION

In conclusion, patients with nephropathic cystinosis have also been described with ease in Egyptian population despite the lack of sophisticated investigations. These cases should be screened for mutation analysis, thus providing further information on the most common *CTNS* gene mutations in the Middle East region.

## CONSENT

All authors declare that 'written informed consent was obtained from the patients' parents for publication of this case report and accompanying images.

## **ETHICAL APPROVAL**

An informed consent has been taken from the legal patients' guardians before enrollment in the study following the principals of the Ethical Committee of Mansoura University Children's Hospital, Egypt.

## **ACKNOWLEDGEMENTS**

We acknowledge the great support of all members of Pediatric nephrology and cardiology units, Mansoura University Children's Hospital, Mansoura, Egypt, and our sincere thanks are also due to patients of the studied families.

## **COMPETING INTERESTS**

Authors have declared that no competing interests exist

## **REFERENCES**

1. Town M, Jean G, Cherqui S, Attard M, Forestier L, Whitmore SA, Callen DF, Gribouval O, Broyer M, Bates GP, van't Hoff W, Antignac C. A novel gene encoding an integral membrane protein is mutated in nephropathic cystinosis. *Nat Genet.* 1998;18:319–324.
2. Shotelersuk V, Larson D, Anikster Y, McDowell G, Lemons R, Bernardini I, Guo J, Thoene J, Gahl WA. CTNS mutations in an American-based population of cystinosis patients. *Am J Hum Genet.* 1998;63:1352-1362.
3. Attard M, Jean G, Forestier L, Cherqui S, van't Hoff W, Broyer M, Antignac C, Town M. Severity of phenotype in cystinosis varies with mutations in the CTNS gene: predicted effect on the model of cystinosis. *Hum Mol Genet.* 1999;8:2507-2514.
4. Mason S, Pepe G, Dall'Amico R, Tartaglia S, Casciani S, Greco M, Bencivenga P, Murer L, Rizzoni G, Tenconi R, Clementi M. Mutational spectrum of the CTNS gene in Italy. *Eur J Hum Genet.* 2003;11:503–508.
5. Anikster Y, Lucero C, Touchman JW, Huizing M, McDowell G, Shotelersuk V, Green ED, Gahl WA. Identification and detection of the common 65-kb deletion breakpoint in the nephropathic cystinosis gene (CTNS). *Mol Genet Metab.* 1999;66:111-116.
6. Al-Nabhani D, El-Naggari M, Al-Sinawi R, Chacko AP, Ganesh A, El Nour I. Nephropathic Cystinosis: First reported case in Oman. *Sultan Qaboos Univ Med J.* 2011;11:503-506.
7. Topaloglu R, Vilboux T, Coskun T, Ozaltin F, Tinloy B, Gunay-Aygun M, Bakkaloglu A, Besbas N, van den Heuvel L, Kleta R, Gahl WA. Genetic basis of cystinosis in Turkish patients: a single-center experience. *Pediatr Nephrol.* 2012;27:115-121.
8. Yeetong P, Tongkobpetch S, Kingwatanakul P, Deekajorndech T, Bernardini IM, Suphapeetiporn K, Gahl WA, Shotelersuk V. Two novel CTNS mutations in cystinosis patients in Thailand. *Gene.* 2012;499:323-325.
9. Wilmer MJ, Schoeber JP, van den Heuvel LP, and Levtchenko EN. Cystinosis: practical tools for diagnosis and treatment. *Pediatr Nephrol.* 2011;26:205–215.
10. Middleton R, Bradbury M, Webb N, O'Donoghue D, Van't Hoff W. Cystinosis. A clinicopathological conference. "From toddlers to twenties and beyond" Adult-Paediatric Nephrology Interface Meeting, Manchester 2001. *Nephrol Dial Transplant.* 2003;18:2492–2495.

11. Levtschenko E, Monnens L. Development of Fanconi syndrome during infancy in a patient with cystinosis. *Acta Paediatr.* 2006;95:379–380.
12. Gahl WA, Thoene JG, Schneider JA. Cystinosis. *N Engl J Med.* 2002;347:111–121.
13. Markello TC, Bernardini IM, Gahl WA. Improved renal function in children with cystinosis treated with cysteamine. *N Engl J Med.* 1993;328:1157–1162.
14. Tsilou ET, Rubin BI, Reed GF, Iwata F, Gahl W, Kaiser-Kupfer MI. Age-related prevalence of anterior segment complications in patients with infantile nephropathic cystinosis. *Cornea.* 2002;21:173–176.
15. de Graaf-Hess A, Trijbels F, Blom H. New method for determining cystine in leukocytes and fibroblasts. *Clin Chem.* 1999;45:2224–2228.
16. Chabli A, Aupetit J, Raehm M, Ricquier D, Chadefaux-Vekemans B. Measurement of cystine in granulocytes using liquid chromatography-tandem mass spectrometry. *Clin Biochem.* 2007;40:692–698.
17. Kalatzis V, Cohen-Solal L, Cordier B, Frishberg Y, Kemper M, Nuutinen EM, Legrand E, Cochat P, Antignac C. Identification of 14 novel CTNS mutations and characterization of seven splice site mutations associated with cystinosis. *Hum Mutat.* 2002;20:439-446.
18. Taranta A, Wilmer MJ, van den Heuvel LP, Bencivenga P, Bellomo F, Levtschenko EN, Emma F. Analysis of CTNS gene transcripts in nephropathic cystinosis. *Pediatr Nephrol.* 2010;25:1263-1267.
19. Besouw MT, Holewijn S, Levtschenko EN, Janssen MC. Non-invasive measurements of atherosclerosis in adult cystinosis patients. *J Inherit Metab Dis.* 2011;34:811-818.
20. Ramappa AJ, Pyatt JR. Pregnancy-associated cardiomyopathy occurring in a young patient with nephropathic cystinosis. *Cardiol Young.* 2010;20:220-222.
21. Ahmed I, Phan TT, Lipkin GW, Frenneaux M. Ventricular noncompaction in a female patient with nephropathic cystinosis: a case report. *J Med Case Reports.* 2009;29:31.

© 2013 Al-Haggar et al.; This is an Open Access article distributed under the terms of the Creative Commons Attribution License (<http://creativecommons.org/licenses/by/3.0>), which permits unrestricted use, distribution, and reproduction in any medium, provided the original work is properly cited.

*Peer-review history:*

*The peer review history for this paper can be accessed here:*  
<http://www.sciencedomain.org/review-history.php?iid=205&id=12&aid=1533>