



Radiological Features of COVID-19 Patients in Hodeidah, Yemen

Fahd Ahmed Suhail ^{a#*} and Mohammed Amod Al Kamarany ^{a,b†*}

^a Center of Tropical Medicine and Infectious Diseases (CTMID) and Department of Radiology, AL Thawra Public Hospital Authority, Hodeidah, Yemen in collaboration with Tropical Medicine Center and Faculty of Medicine and Health Sciences, Hodeidah University, Yemen.

^b Health and Nutrition Program, Save the Children International (SCI), Hodeidah Office, Yemen.

Authors' contributions

This work was carried out in collaboration between both authors. Author FAS diagnosed and described the radiological features of COVID-19 and collected the data and wrote the clinical reports. Author MALK wrote, revised and edited the final manuscript. Both authors read and approved the final manuscript.

Article Information

DOI: 10.9734/AJRID/2021/v8i430256

Editor(s):

- (1) Dr. Hetal Pandya, SBKS Medical Institute & Research Center, India.
- (2) Dr. Giuseppe Murdaca, University of Genoa, Italy.

Reviewers:

- (1) Salehodin Bouya, Zahedan University of Medical Sciences, Iran.
- (2) Astrida Velena, Latvian Institute of Organic Synthesis, Latvia.
- (3) Mona Fazel Ghaziyani, Tabriz University of Medical Sciences, Iran.

Complete Peer review History, details of the editor(s), Reviewers and additional Reviewers are available here: <https://www.sdiarticle5.com/review-history/67874>

Original Research Article

Received 02 November 2021
Accepted 04 December 2021
Published 22 December 2021

ABSTRACT

Background: The radiological techniques namely chest radiography (chest X-ray) and computerized tomography (CT) scan play a major role not only in the early detection and diagnosis, especially for false negative Real Time-Polymerase Reaction (RT-PCR) tests and in admission criteria, monitoring the clinical course and the disease severity.

Objective: The study aimed to describe the radiological features of chest X-ray and CT scan in coronavirus diseases 2019 (COVID-19) patients, Hodeidah, Yemen.

Methodology: A descriptive study (a case series) included 49 patients with COVID-19, confirmed by RT-PCR who were admitted in isolation department of COVID-19, Center of Tropical Medicine and Infectious Diseases (CTMID), AL Thawara Public Hospital Authority, Hodeidah, Yemen who

Consultant and Assistant Professor in Radiology;

† Consultant and Associate Professor in Pharmacology of Infectious Diseases and Scientific Consultant on COVID-19 Humanitarian Project;

*Corresponding author: E-mail: alkamarany@gmail.com, doctorfahd96@gmail.com;

underwent serial chest X-ray and CT scan, from 1st June to 31st December 2021. The cases reports of patients from 3 to 80 years old. Image features and their distribution were analyzed and the COVID-19 Reporting and Data System (CO-RADS) for level of suspicion of COVID-19 infection was applied.

Results: The results showed that 21 /49 patients (42.86 %) of CO-RAD 4 and 28 /49 patients (57.14 %) of CO-RAD 5. The most patterns were 42/49 patients (85.71 %) of ground glass opacification (GGO), 40/49 patients (81.63%) of bilateral involvement , 41/49 patients (83.67 %) of multi-lobar involvement, 37/49 patients (75,51 %) of peripheral distribution , 15/49 patients (30.61 %) of consolidation pattern and 3/49 patients (6.12%) of crazy paving pattern. On the other hand , in the youngest patients less than 50 year ,79 % had GGO, and 21 % had lung consolidations ,while in the patients over 50 year ,GGO were presented in 56 % and consolidations in 44 %. In addition, the lung involvement range of patients was from 40 to 95 % and the median was 60 %. The lung involvement was represented in the patients more than 50 year as 60 – 95 % while in the patients less than 50 years was represented as 40 – 55 %. The lung involvement of death patients was 85 to 95 % of non-chronic diseases and 60 to 70 % of comorbidity and coinfection.

Conclusion: The study concluded that different radiological patterns and features were reported in elderly patients with COVID-19 infection associated with risk factors (comorbidity and coinfection). The radiological techniques have good predictive values on severity and mortality. Also can support the clinicians staff in early detection, early triage, criteria admission, and effective management of COVID-19 infection.

Keywords: Radiological; features; chest X-ray; CT scan; COVID-19; Hodeidah; Yemen.

1. INTRODUCTION

Radiological techniques have an important role to play in the diagnosis and assessment of the coronavirus disease 2019 (COVID-19). Radiological techniques namely radiography (X-ray) and computed tomography (CT) scan are primarily to assess the severity and/or impact of COVID-19 on patients who have tested positive for the virus and who are experiencing severe and/or problematic symptoms [1] .

World Health Organization (WHO) published rapid advice guide examines the evidence and makes recommendations for the use of chest imaging in acute care of adult patients with suspected, probable or confirmed COVID-19. Imaging modalities considered are X-ray and CT scan. This guide addresses the care pathway from presentation of the patient to a health facility to patient recovery. It considers different levels of disease severity, from asymptomatic individuals to critically ill patients [2].

According to a Fleischner Society consensus statement published on 7 April 2020, imaging is not indicated in patients with suspected COVID-19 and mild clinical features unless they are at risk for disease progression, imaging is indicated in a patient with COVID-19 and worsening respiratory status, in a resource-constrained environment, imaging is indicated for medical triage of patients with suspected COVID-19 who

present with moderate-severe clinical features and a high pretest probability of disease [3-5].

The study aimed to describe the radiological patterns and features of chest X-ray and CT scan of COVID-19 patients in Hodeidah, Yemen.

2. METHODOLOGY

2.1 Study Area

Hodeidah Governorate is located on the western , flat and narrow coastal plain between the foothills of the highlands and the red sea. Hodeidah is the fourth largest Governorate in Yemen in the term of population which reaches to about (2157552). The area is 13500 km² involves 26 Districts, and a lot of islands in the red sea. The weather is typically hot and humid and the temperatures sometimes exceeding 38 to 40° C. During the rest of the year temperature range between 27-35 °C. This region is known to have high conflict area since the 26th of March 2015. Hodeidah , Yemen also is considered as an endemic zone for numerous infectious diseases namely dengue and malaria [6-9].

2.2 Study Design

This work was designed in a descriptive study (a series case). The patients who were admitted in the COVID-19 Isolation Department, Center of

Table 1. CO-RAD level of suspicion of COVID-19 infection

| | | |
|----------|---------------|--|
| CO-RAD 1 | No | Normal |
| CO-RAD 2 | Low | Abnormalities consistent with infections other than COVID-19 |
| CO-RAD 3 | Indeterminate | Unclear whether COVID -19 is present |
| CO-RAD 4 | High | Abnormalities suspicious for COVID -19 |
| CO-RAD 5 | Very high | Typical COVID-19 |
| CO-RAD 6 | PCR + | |

Tropical Medicine and Infectious Diseases (CTMID), AL Thawara Public Hospital Authority, Hodeidah, Yemen from 1st June to 31st December 2020.

2.3 Chest X-ray and CT Scan Protocol

Chest X-ray was performed in the antero-posterior projection. All images were stored in a picture archiving and communication system (AGFA Computed Radiography). Patients with CT scan were received a non-contrast chest CT scan (unless iodinated contrast medium is indicated), with reconstructions of the volume at 0.625 mm to 1.5 mm slice thickness (gapless).

If iodinated contrast medium is indicated, such as in CT pulmonary angiogram (CTPA), a non-contrast scan should be considered prior to contrast administration, as contrast may impact the interpretation of results. Multi-detector CT (MDCT) machine with High-resolution CT (HRCT) protocol was applied. The Dutch Association for Radiology (NVvR) proposed a CT scan scoring system for COVID-19. They called it COVID-19 Reporting and Data System (CO-RADS) to ensure CT scan reporting is uniform and replicable [10-12].

3. RESULTS

3.1 Radiological Finding According to Age and Sex

The patients were classified into 2 groups according to their age, patients younger than 50 year and patients older than 50 year. In the youngest group of patients, 79 % had ground glass opacification (GGO), and 21% had lung consolidations (Fig 3 and 4), while in the group of patients over 50 year, GGO were present in 56

% and consolidations in 44 % (Fig. 5 and 6). Males were significantly overrepresented in this group compared with females ($X^2 = 19.61$; $p = 0.0001$) (Table 2).

3.2 Radiological Finding According to Severity

Lung involvement of COVID-19 patients was diagnosed in admitted patients using CT scan. The lung involvement was represented in the patients more than 50 year as 60 – 95 % while in the patients less than 50 year was represented as 40 – 55 %. The lung involvement range of COVID-19 patients was from 40 to 95 % and the median was 60 %. The relationship between the lung involvement (%) and mortality was reported where the lung involvement in death patients was 85 to 95 % of non-chronic diseases and 60 to 70 % of comorbidity and coinfection (Table 3).

3.3 Radiological Patterns

CO-RAD levels of suspicion of COVID-19 infection was summarized in Table 4 and Figure 1. 21/49 patients (42.86 %) of CO-RAD 4 and 28/49 patients (57.14 %) of CO-RAD 5. On the other hand, the radiological features were reported and the most patterns were 42/49 patients (85.71 %) of GGO, 40/49 patients (81.63%) of bilateral involvement, 41/49 patients (83.67 %) of multi-lobar involvement, and 37/49 patients (75.51 %) of peripheral distribution. The least patterns were 15/49 patients (30.61 %) of consolidation pattern and 3/49 patients (6.12%) of crazy paving pattern (Fig. 2). Figure 3 to 6 showed the different CO-RAD levels and radiological patterns for COVID-19 patients.

Table 2. Sex and age data of COVID-19 patients in Hodeidah, Yemen (N = 49)

| Variables | Number(n) | Ratio (%) | X^2 | p – value |
|-----------|-----------|-----------|-------|-----------|
| Gender | | | | |
| Male | 40 | 81.63 | 19.62 | 0.00001* |
| Female | 9 | 18.37 | | |
| Total | 49 | 100 | | |
| Age | | | | |
| < 50 | 16 | 32.65 | 5.898 | 0.015 * |
| > 50 | 33 | 67.34 | | |
| Total | 49 | 100 | | |

* Significant (p - value < 0.05)

Table 3. Radiological finding according to severity (N: 49)

| Comorbidity | Morbidity (n) | Mortality (n) | Lung involvement of death cases (%) |
|--------------------------------|----------------------|----------------------|--|
| Diabetes | 9 | 3 | 60 – 70 % |
| Diabetes and Chronic Diseases | 8 | 4 | 60 – 70 % |
| Heart disease and asthma | 2 | 1 | 66 % |
| Heart disease and hypertension | 6 | 3 | 60 – 70 % |
| Asthma | 6 | 4 | 60 – 70 % |
| Renal Failure | 2 | 1 | 65 % |
| Coinfection | | | |
| Tuberculosis | 1 | 0 | - |
| Hepatitis C | 1 | 1 | 65 % |
| Non | 14 | 6 | 85 – 95 % |
| Total | 49 | 23 | 60 – 95 % |

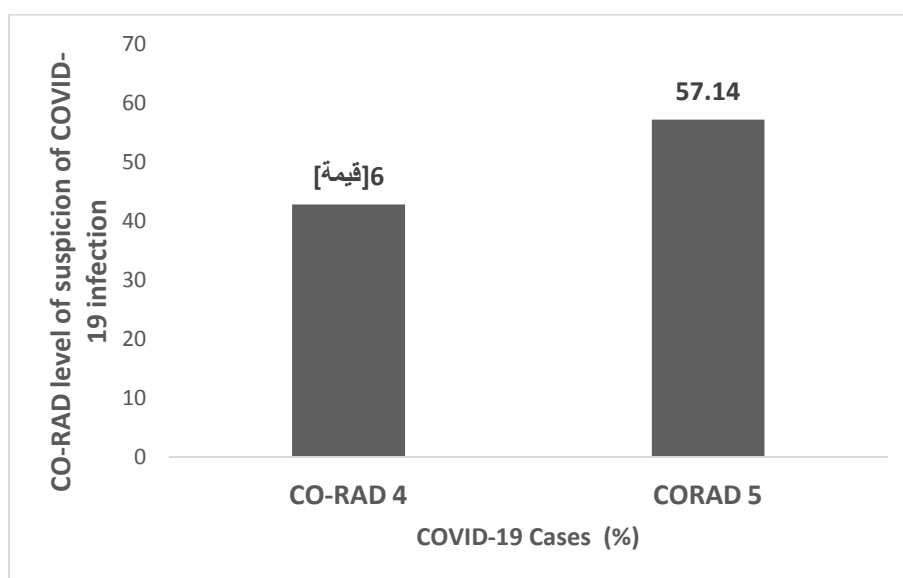


Fig. 1. CO-RAD level of suspicion of COVID – 19 infection (%)

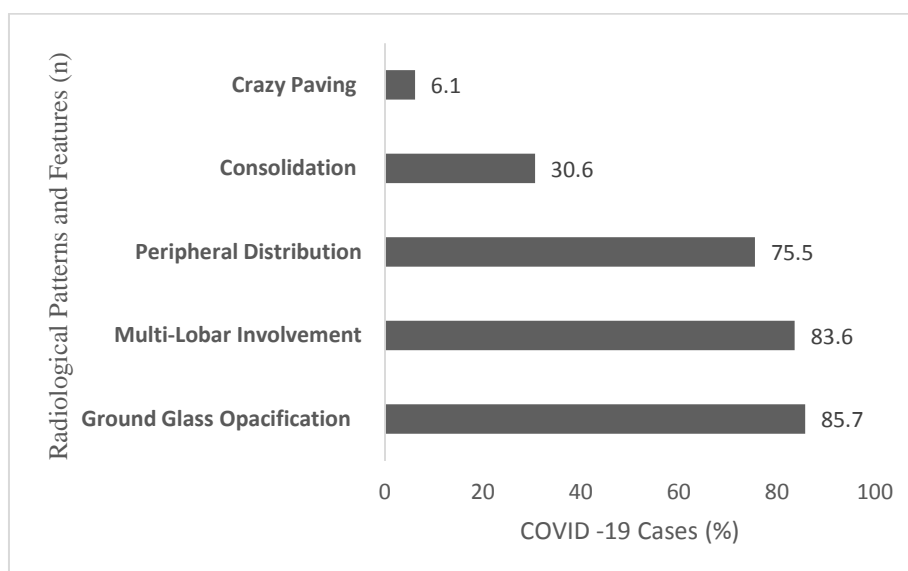


Fig. 2. Radiological features and patterns (%)

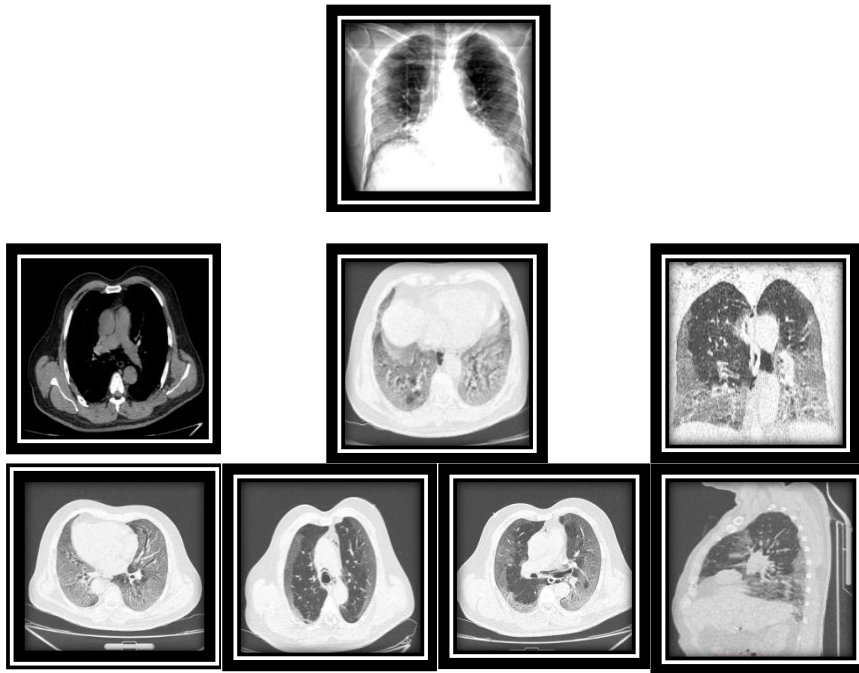


Fig. 3. 40 year old male, who had fever for ten days with progressive coughing and shortness of breath. Saturation at admission was 80 %. X-ray finding “posteroanterior (PA) chest X-ray shows bilateral GGO with peripheral predominance. CT scan finding “ bilateral multi-lobar symmetrical GGO with a posterior and peripheral predominance, no significant enlarged lymph nodes, no pleural effusion. 50% of the lungs are involved. CO-RAD 4 likely COVID-19 and RT-PCR positive

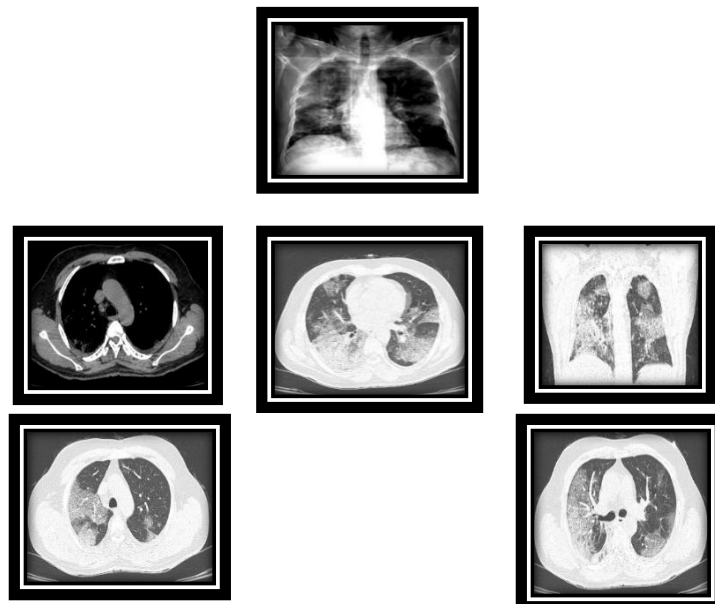


Fig. 4. 45 year old male, who had fever for 15 days with shortness of breath and joint pain. Saturation at admission was 85 %. X-ray finding “ PA chest X- ray shows peripheral and lower opacities of both lungs. CT scan finding “Bilateral GGO with inter-lobar and lobular reticulations consistent with crazy paving appearance, no significant enlarged lymph nodes, no pleural effusion. About 40 % of the lungs are involved. CO-RAD 4 likely COVID-19 with RT-PCR positive

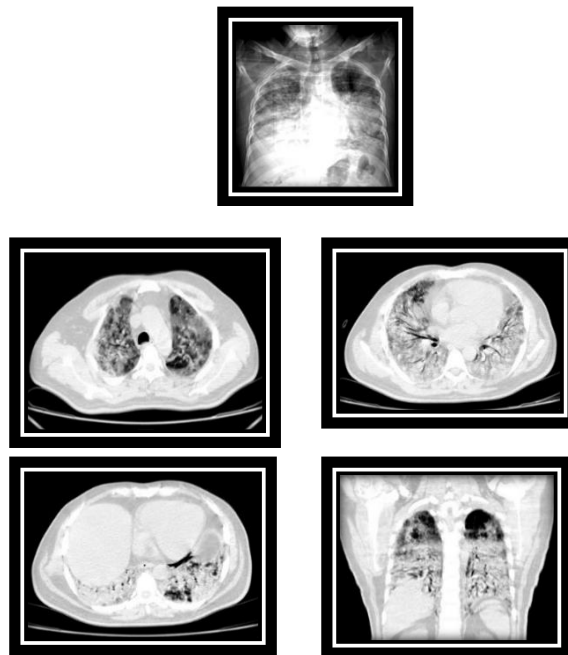


Fig. 5. 58 year old male, who had fever for 20 days with progressive coughing and shortness of breath. Saturation at admission was 63 %. X-ray finding “ PA chest X-ray shows bilateral consolidation mainly involving the lower lobes with peripheral predominance in the upper lobes. CT scan finding “Bilateral consolidations of both lung fields with small areas of GGO mainly seen in the upper lobes the air bronchogram noted, reactive lymph nodes, no pleural effusion. 85% of the lungs are involved. CO-RADS 5 high likely COVID-19 with RT- PCR positive

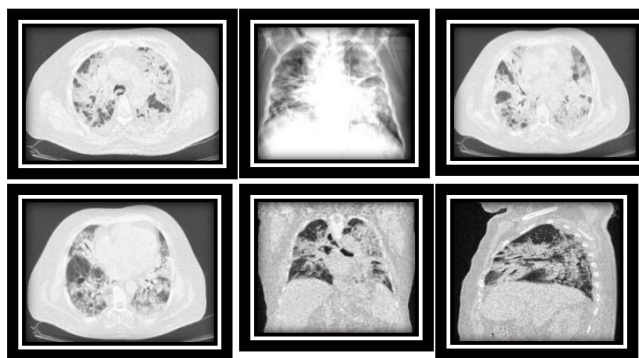


Fig. 6. 80 year old male, who had fever for 30 days with shortness of breath. Saturation at admission was 60 %. X-ray finding “ PA chest X-ray shows bilateral consolidation with reticulation” . CT scan finding “ Bilateral consolidations of both lung fields associated with reticular pattern and traction mild bronchiectasis, reactive lymph nodes, no pleural effusion. More than 50 % of the lungs are involved”. CO-RAD 5 high likely COVID-19 with RT-PCR positive

Table 4. CO-RAD level of suspicion of COVID – 19 infection (N:49)

| | | |
|----------|---------------|----------|
| CO-RAD 1 | No | 0 |
| CO-RAD 2 | Low | 0 |
| CO-RAD 3 | Indeterminate | 0 |
| CO-RAD 4 | High | 21 cases |
| CO-RAD 5 | Very high | 28 cases |
| CO-RAD 6 | PCR + | NA |

4. DISCUSSION

Plain X-ray, although less sensitive than chest CT scan, chest radiography is typically the first-line imaging modality used for patients with suspected COVID-19 [10]. For ease of decontamination, use of portable radiography units is preferred [12].

Findings are most extensive about 10-12 days after symptom onset [13]. The radiological features were reported in Hodeidah, Yemen in different patterns namely GGO pattern, consolidation pattern, consolidation with reticulation and bronchiectasis pattern, and crazy paving pattern. Our patterns similar for many studies in different countries, Rodrigues et al and Wong et al described that the most frequent findings are airspace opacities, whether described as consolidation or, less commonly, GGO. The distribution is most often bilateral, peripheral, and lower zone predominant [5,13]. In contrast to parenchymal abnormalities, pleural effusion is rare.

The British Society of Thoracic Imaging (BSTI) have published a reporting for the plain chest X-ray appearances of potential COVID-19 cases [5]. Classic/probable COVID-19 (lower lobe and peripheral predominant multiple opacities that are bilateral > unilateral). Indeterminate for COVID-19 (does not fit classic or non-COVID-19 descriptors). Non-COVID-19 (pneumothorax/ lobar pneumonia / pleural effusion(s) / pulmonary edema / other). Normal (COVID-19 not excluded).

The primary findings on CT scan in adults have been reported as GGO (bilateral, subpleural, peripheral, basal distribution), crazy paving appearance (GGO and inter-/intra-lobular septal thickening), consolidation, bronchovascular thickening in the lesion, traction bronchiectasis [14 – 20]. Atypical CT scan findings, these findings only seen in a small minority of patients should raise concern for superadded bacterial pneumonia or other diagnoses as mediastinal lymphadenopathy, pleural effusions: may occur as a complication of COVID-19, multiple tiny pulmonary nodules (unlike many other types of viral pneumonia) , tree-in-bud, pneumothorax and cavitation [5, 21,22]. Temporal CT scan changes, four stages on CT scan have been described 1) early/initial stage (0-4 days): normal CT scan or GGO only (up to half of patients have normal CT scan within two days of symptom onset); 2) progressive stage (5-8 days):

increased GGO and crazy paving appearance; 3) peak stage (9-13 days): consolidation; and 4) absorption stage (>14 days): with an improvement in the disease course, "fibrous stripes" appear and the abnormalities resolve at one month and beyond [17, 22-24].

GGO was first described by the Fleischner Society. GGO is defined as blurred areas with slightly increased lung density and the absence of shading of the bronchi and edges of blood vessels, which may be attributed to the partial displacement of air resulting from partial air filling or interstitial thickening. GGO in several studies usually appear on 0–5 days after the onset of initial symptoms. Consolidations " Pulmonary consolidation refers to the replacement of alveolar air by pathological fluids, cells, or tissues and manifests an increase in the density of the lung parenchyma, resulting in obscuring the margins of vessels and airway walls . Consolidation usually is observed in the progressive or the peak stage (4–14 days after the onset of the initial symptoms). The crazy-paving pattern is another important CT scan feature, which shows GGO with superimposed interlobular and intra-lobular septal thickening, akin to irregular paving stones (This sign represents alveolar edema and interstitial inflammatory reaction). The appearance of crazy-paving patterns is frequently observed in CT scan findings during disease progression (5–8 days after the illness) or in severe cases of COVID-19 [3, 25-27].

In Italy, the following alterations were more commonly observed: patients with lung consolidations (57.7%), (62.8%) with GGO, (23.5%) with nodules and (66.6%) with reticular–nodular opacities. Patients with consolidations and GGO coexistent in the same radiography were (35.5%) of total. Peripheral (57.7%) and lower zone distribution (58.5%) were the most common predominance. Moreover, bilateral involvement (69.2%) was most frequent than unilateral one [28]. Other study in China, the predominant pattern of abnormality observed was bilateral (79%), peripheral (54%), ill-defined (81%), and GGO (65%), mainly involving the right lower lobes (27%) of affected segments [29].

Other study in China reported the CT scan images showed pure GGO in 77% and GGO with reticular and/or interlobular septal thickening in 75% patients. GGO with consolidation was present 59%, and pure consolidation was

present in 55% patients. 86% had bilateral lung involvement, while 80% involved the posterior part of the lungs and 86% were peripheral. Patients older than 50 years had more consolidated lung lesions than did those aged 50 years or younger [30]. In addition, in the youngest group of patients (less than 50 year), 79 % had GGO, and only 21 % had lung consolidations. Atypical findings were reported more common in older patients. This result agreed with previous study was reported by Song et al . 77% had GGO, and only 23% had lung consolidations, while in the group of patients over 50 years, GGO were present in 56% and consolidations in 44% and the result similar to a study by Song et al , the incidence of consolidation was significantly higher in older patients (> 50 years) [30,31]. Our finding reported 6.1 % of crazy paving pattern that agreed with study of the Bao et al that had incidence of 14.81% [32]

Finally, in our tertiary center, CT scan examination is usually performed (generally after a chest X-ray) only in specific situations: in case of clinical-radiological discordance (when chest X-ray is negative for infective lung involvement, but there is a high clinical-epidemiological suspect), in case of acute complication (pulmonary embolism or severe respiratory failure) or after intubation before transporting patient to ICU.

Limitations of the study: There are some limitations in this study that needs to be considered. The small samples size in confirmation of cases. The study were limited on severe and critical cases only therefore, the study will include in the future the mild and moderate cases .

5. CONCLUSION

The study concluded that different radiological patterns and features were reported in elderly patients with COVID-19 infection associated with risk factors (comorbidity and coinfection). The radiological techniques have good predictive values on severity and mortality. Also can support the clinicians staff in early detection, early triage, criteria admission, and effective management of COVID-19 infection.

DISCLAIMER

The authors declare that the research was conducted in the absence of any commercial or

financial relationships that could be construed as a potential conflict of interest.

CONSENT

As per international standard or university standard, patients' written consent has been collected and preserved by the author(s).

ETHICAL APPROVAL

As per international standard or university standard written ethical approval has been collected and preserved by the author(s).

FUNDING

This study was Funded by COVID-19 Humanitarian Response Project , Health and Nutrition Program, Save the Children International (SCI), Hodiedah Office, Yemen Country. The fund is humanitarian response for diagnose and treatment, and control of COVID-19 pandemic in conflict area. The publication fee is not supported in this fund.

ACKNOWLEDGEMENTS

The authors would like to thank the supervisor and medical staff of the COVID-19 isolation department, Center of Tropical Medicine and Infectious Diseases (CTMID), AL Thawara Public Hospital Authority, Hodeidah , Yemen for their fruitful assistance .

COMPETING INTERESTS

Authors have declared that no competing interests exist.

REFERENCES

1. Practice Pointer. The role of chest radiography in confirming covid-19 pneumonia. BMJ. 2020;370. DOI:<https://doi.org/10.1136/bmj.m2426>
2. World Health Organization (WHO) . Use of chest imaging in COVID-19. A rapid advice guide. COVID-19: Clinical care; 2020. Available:<https://www.who.int/publications/i/item/use-of-chest-imaging-in-covid-19> [Accessed June 11, 2020]
3. Rubin Geoffrey D., Linda B. Haramati and Jeffrey P. Kanne et al. The role of chest imaging in patient management during the COVID-19 pandemic: A multinational

- consensus statement from the fleischner society. Practice Guideline Chest. 2020; 296(1):172 – 180.
DOI: 10.1016/j.chest.2020.04.003.
4. Constantine A. Raptis, Mark M. Hammer, Ryan G. Short, Amar Shah, Sanjeev Bhalla, Andrew J. Bierhals, Peter D. Filev, Michael D. Hope, Jean Jeudy, Seth J. Kligerman, Travis S. Henry. Chest CT and Coronavirus Disease (COVID-19): A Critical Review of the Literature to Date. *AJR Am J Roentgenol.* 2020;215(4):839-842. DOI: 10.2214/AJR.20.23202.
 5. Rodrigues JCL, Hare SS, Edey A, Devaraj A, Jacob J, Johnstone A, McStay R, Nair A, Robinson G. An update on COVID-19 for the radiologist - A British society of Thoracic Imaging statement. *Clin Radiol.* . 2020;75(5):323–325.
DOI: 10.1016/j.crad.2020.03.003.
 6. CSO Statistical Year Book 2004; Ministry of Planning and International Cooperation: Sana'a, Republic of Yemen; 2005.
 7. CSO Statistical Year Book 2006; Ministry of Planning and International Cooperation: Sana'a, Republic of Yemen, 2007.
 8. Al-Tamimi NA, Al-Hodeidah's displaced face continued hardship , *Human Rights* , 2019;02:26
 9. Al-Areeqi A, Alghalibi S , Yusuf Q, Al-Masrafi , and Amod AL Kamarany M . Epidemiological characteristic of malaria coinfectd with dengue fever in Hodeidah, Yemen . *International Journal of Tropical Disease & Health.* 2020;40(3): 2020 .
 10. Kooraki S, Hosseiny M, and Myers L, Gholamrezanezhad A. Coronavirus (COVID-19) Outbreak: What the Department of Radiology Should Know. *J Am Coll Radiol.* 2020;179(4):447-451.
DOI: 10.1016/j.jacr.2020.02.008
 11. Prokop M, van Everdingen W, van Rees Vellinga T, Quarles van Ufford J, Stöger L, Beenen L, Geurts B, Gietema H, Krdzalic J, Schaefer-Prokop C, van Ginneken B, and Brink M. CO-RADS - A categorical CT assessment scheme for patients with suspected COVID-19: definition and evaluation. *Radiology* . 2020;296(2): E97-E104. DOI: 10.1148/radiol.2020201473.
 12. Ai T, Yang Z, Hou H, Zhan C, Chen C, Lv W, Tao Q, Sun Z, and Xia L. Correlation of Chest CT and RT-PCR Testing in Coronavirus Disease 2019 (COVID-19) in China: A Report of 1014 Cases. *Radiology.* 2020;296(2):E32-E40
DOI:https://doi.org/10.1148/radiol.2020200642
 13. Wong HYF, Lam HYS, Fong AH, Leung ST, Chin TW, Lo CSY, Lui MM, Lee JCY, Chiu KW, Chung T, Lee EYP, Wan EYF, Hung FNI, Lam TPW, Kuo M, Ng MY. Frequency and distribution of chest radiographic findings in COVID-19 positive patients. *Radiology.* 2020;296(2):E72-E78
DOI: 10.1148/radiol.2020201160.
 14. American College of Radiology (ACR). Recommendations for the Use of Chest Radiography and Computed Tomography (CT) for Suspected COVID-19 Infection. 2020.
Available:https://www.acr.org/Advocacy-and-Economics/ACR-Position-Statements/Recommendations-for-Chest-;Radiography-and-CT-for-Suspected-COVID19-Infection
[Accessed March 11, 2020]
 15. Canadian Society of Thoracic Radiology and Canadian Association of Radiologists' Statement on COVID -19 - CAR - Canadian Association of Radiologists; 2020.
 16. Wang D, Hu B, Hu C, Zhu F, Liu X, Zhang J, Wang B, Xiang H, Cheng Z, Xiong Y, Zhao Y, Li Y, Wang X, and Peng Z. Clinical Characteristics of 138 Hospitalized Patients With 2019 Novel Coronavirus-Infected Pneumonia in Wuhan, China. *JAMA.* 2020;323(11):1061–1069.
DOI:10.1001/jama.2020.1585
 17. Pan F, Ye T, Sun P, Gui S, Liang B, Li L, Zheng D, Wang J, Hesketh RL, Yang L, and Zheng C. Time Course of Lung Changes On Chest CT During Recovery From 2019 Novel Coronavirus (COVID-19) *Radiology* . 2020;295(3):715–721.
DOI:https://doi.org/10.1148/radiol.2020200370
 18. Shi H, Han X, Jiang N, Cao Y, Osamah A, Gu J, Fan Y, and Zheng C. Radiological findings from 81 patients with COVID-19 pneumonia in Wuhan, China: a descriptive study. *Lancet Infect Dis.* 2020;20(4):425-434.
DOI: 10.1016/S1473-3099(20)30086-
 19. Lee EYP, Ng M-Y, Khong PL. COVID-19 pneumonia: what has CT taught us?. *Lancet Infect Dis.* 2020;20(40):84-385.
DOI: 10.1016/S1473-3099(20)30134-1.
 20. Zhao W, Zhong Z, Xie X, Yu O, Liu J. Relation between chest CT findings and

- clinical conditions of coronavirus disease (COVID-19) Pneumonia: A multicenter study. *AJR Am J Roentgenol.* 2020;215 (1): W5-W5. DOI: 10.2214/AJR.20.22976.
21. Perlman P. Another decade, another coronavirus. *N Engl J Med.* 2020;382:760-762 DOI: 10.1056/NEJMe2001126
22. Kanne JP, Little BP, Chung JH, Elicker BM, Ketani LH. Essentials for radiologists on COVID-19: An update—radiology scientific expert panel. *Radiology.* 2020;296(2):E113-E114 DOI: 10.1148/radiol.2020200527.
23. Pan Y, Guan H, Zhou S, Wang Y, Li Q, Zhu T, Hu O, Xia L. Initial CT findings and temporal changes in patients with the novel coronavirus pneumonia (2019-nCoV): a study of 63 patients in Wuhan, China. *Eur Radiol.* 2020;30(6):3306-3309. DOI: 10.1007/s00330-020-06731-x.
24. Nederlandse Vereniging voor Radiologie. Handreiking Standaardverslag. CT-thorax COVID inclusief CO-RADS en CT-score . CO-RADS – A categorical CT assessment scheme for patients with suspected COVID-19: definition and evaluation. *Radiology.* 2020;201473. DOI:https://doi.org/10.1148/radiol.2020201473
25. Zuo H. Contribution of CT features in the diagnosis of COVID-19. *Can Respir J.* 2020;2020:1237418. doi: 10.1155/2020/1237418
26. Hansell DM, Bankier AA, MacMahon H, McLoud TC, Müller NL, Remy J. Fleischner society: glossary of terms for thoracic imaging. *Radiology.* 2008;246(3):697–722. DOI: 10.1148/radiol.2462070712.
27. Pan F, Ye T, Sun P, et al. Time course of lung changes at chest CT during recovery from coronavirus disease 2019 (COVID-19) *Radiology.* 2020;295(3):715–721. DOI: 10.1148/radiol.2020200370.
28. Cozzi D, Albanesi M, Cavigli E, Moroni C, Bindi A, Luvarà S, Lucarini S, Busoni S, Mazzoni LN, Miele V. Chest X-ray in new coronavirus disease 2019 (COVID-19) infection: findings and correlation with clinical outcome. *Radiol Med.* 2020;1 (8) DOI: 10.1007/s11547-020-01232-9
29. Shi H, Han X, Jiang N, Cao Y, Alwalid O, Gu J, Fan Y, Zheng C. Radiological findings from 81 patients with COVID-19 pneumonia in Wuhan, China: a descriptive study. *Lancet Infect Dis.* 2020;20(4):425–434. DOI:https://doi.org/10.1016/S14733099(20)30086-4
30. Song F, Shi N, Shan F, Zhang Z, Shen J, Lu H, Ling Y, Jiang Y, Shi Y. 2020. Emerging coronavirus (2019-nCoV) pneumonia. *Radiology;* 2020. In press DOI:http://dx.doi.org/10.1148/radiol.2020200274
31. Sánchez-Oro R, Nuez J T, and Martínez-San G. Radiological findings for diagnosis of SARS-CoV-2 pneumonia (COVID-19). *Med Clin (Barc).* 2020;155 (1):36–40.
32. Bao C, Liu X, Zhang H, Li Y, Liu J. Coronavirus disease 2019 (COVID-19) CT findings: a systematic review and meta-analysis. *J Am Coll Radiol.* 2020:S1546-1440(20)30262-3. doi: https://doi.org/10.1016/j.jacr.2020.03.006. Online ahead of print.

© 2021 Suhail and Amod AL Kamarany; This is an Open Access article distributed under the terms of the Creative Commons Attribution License (<http://creativecommons.org/licenses/by/4.0>), which permits unrestricted use, distribution, and reproduction in any medium, provided the original work is properly cited.

Peer-review history:
The peer review history for this paper can be accessed here:
<https://www.sdiarticle5.com/review-history/67874>