

Case Report on Epilepsy with Cough Aura

Mohamed Hamdy Ibrahim¹, Ahmed El Mansory², Shivram Kumar³, Janhavi Sirsat³

¹Department of Neurology, GMC Hospital, Ajman, UAE

²Department of Pulmonology, GMC Hospital, Ajman, UAE

³Gulf Medical University, Ajman, UAE

Email: mohamedhamdy_neuro2007@yahoo.com

Received 10 February 2015; accepted 24 February 2015; published 28 February 2015

Copyright © 2015 by authors and Scientific Research Publishing Inc.

This work is licensed under the Creative Commons Attribution International License (CC BY).

<http://creativecommons.org/licenses/by/4.0/>



Open Access

Abstract

The case study is aimed at providing a more thorough analysis of a case of Epilepsy presented with an unusual aura of cough. The study hopes to generate an interest for further studies into the topic and focuses on abnormal unusual presentations of auras. Cough as an aura is not a common presentation. Any stereotyped repeated clinical phenomenon should consider being epileptic in its origin.

Keywords

Epilepsy, Cough, Aura, Chronic Bronchitis

1. Introduction

The definition of Epilepsy and Epileptic seizures, as per the International League Against Epilepsy (ILAE) in 2005, states that an epileptic seizure is a transient occurrence of signs and/or symptoms due to abnormal excessive or synchronous neuronal activity in the brain [1]. Epilepsy is a disease characterized by an enduring predisposition to generate epileptic seizures and by the neurobiological, cognitive, psychological, and social consequences of this condition [1].

2. Case Presentation

A 45-year-old Comoros man presents to the hospital with history of attacks of seizure 2 to 3 times a day since the past 20 days. He also gives history of a dry cough for the first 15 days followed by a productive cough with white sputum associated with fever and dyspnea for the next 5 days. According to the patient's wife, he would lose consciousness after severe cough followed by development of a tonic-clonic jerk of the right arm. The seizure is also associated with dripping saliva and foaming from the mouth. The entire episode lasts for around 60 seconds.

The patients' past medical and surgical history includes an appendectomy done in 2011. He does not have any allergies or co-morbidities. His family history is significant for type 2 diabetes mellitus. He gives history of smoking one pack of cigarette per day and says he quit drinking alcohol.

On examination the patient had a pulse of 72 beats/minute, blood pressure of 120/70 mmHg, temperature of 36.2°C and respiratory rate of 21 breaths/minute. He is alert, oriented, conscious and stable. There are no signs of dehydration or peripheral edema.

Respiratory examination revealed bilateral equal air entry with scattered sonorous rhonchi. CNS examination revealed intact sensation with a power of 5/5.

CBC revealed leukocytosis (20,000/UL) with lymphocytosis (34%). Serum electrolytes, LFTs and RFTs were normal. ABG showed decreased pO₂ (hypoxia), pCO₂ (hypocapnia) and O₂ saturation.

MRI of the brain without contrast as seen in **Figure 1** revealed bilateral basal ganglia calcifications. It also revealed bilateral maxillary and left ethmoid sinusitis along with hypertrophied left inferior nasal turbinate.

EEG report in **Figures 2-4** shows no significant changes upon photic stimulation. During hyperventilation the patient developed an unexplained episode of cough, which was followed by a myoclonic jerk of the right arm and a post-ictal confusion state making automatic movements. The scan revealed simultaneous bouts of spikes and slow waves lasting for a few seconds during this event. The patient was not able to recall any part of the event. As a whole the EEG picture is suggestive of generalized epileptic activity.

The patient was started on Nebulization, Perfalgum (IV), Lamictel (Tab), Ziloric (Tab), Klacid (Tab), Mero-penem (IV), Hydrocortisone (IV) and discharged on Spriva (Tab), Klacid (Tab), Acetylcysteine (Tab), Epanutin (Tab) and Lamictal (Tab).

Upon follow-up, the patient was compliant with the medication and revealed that the frequency of seizure attacks had drastically reduced along with the cough.

3. Discussion

Although studies have shown cases of epilepsy with aura such as somatosensory aura [2], olfactory aura [3], abdominal aura [4], etc., no case regarding epilepsy with cough aura has been reported.

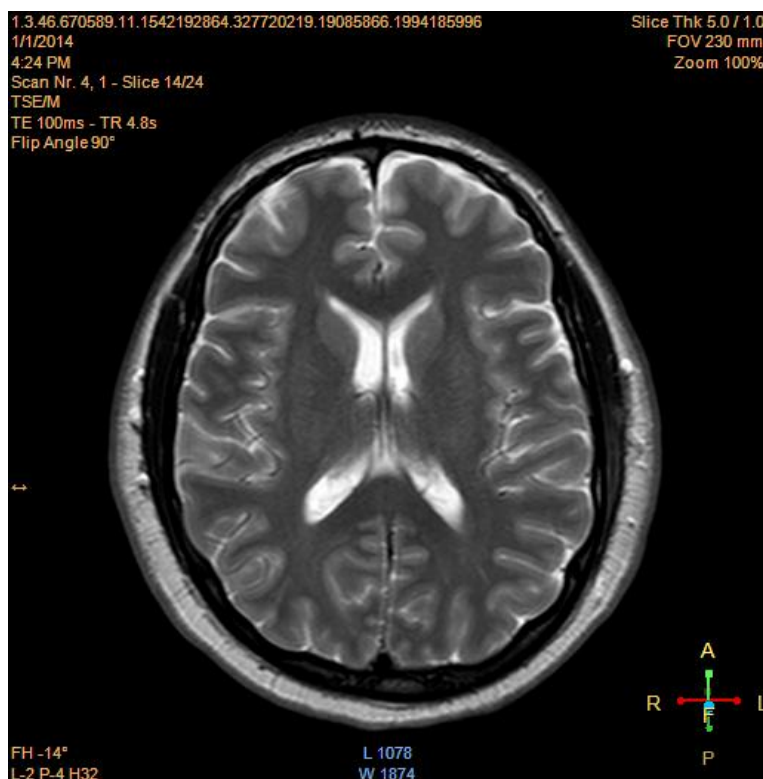


Figure 1. MRI Brain showing bilateral basal ganglia calcification.

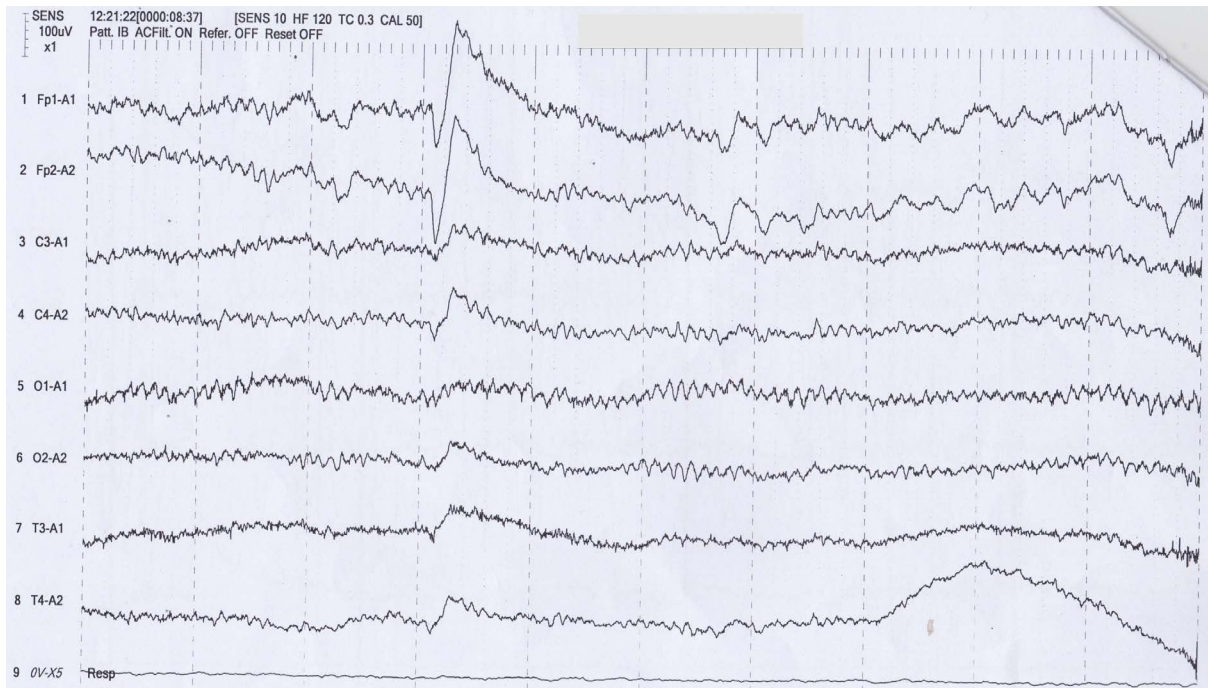


Figure 2. EEG report showing normal rhythm before cough.

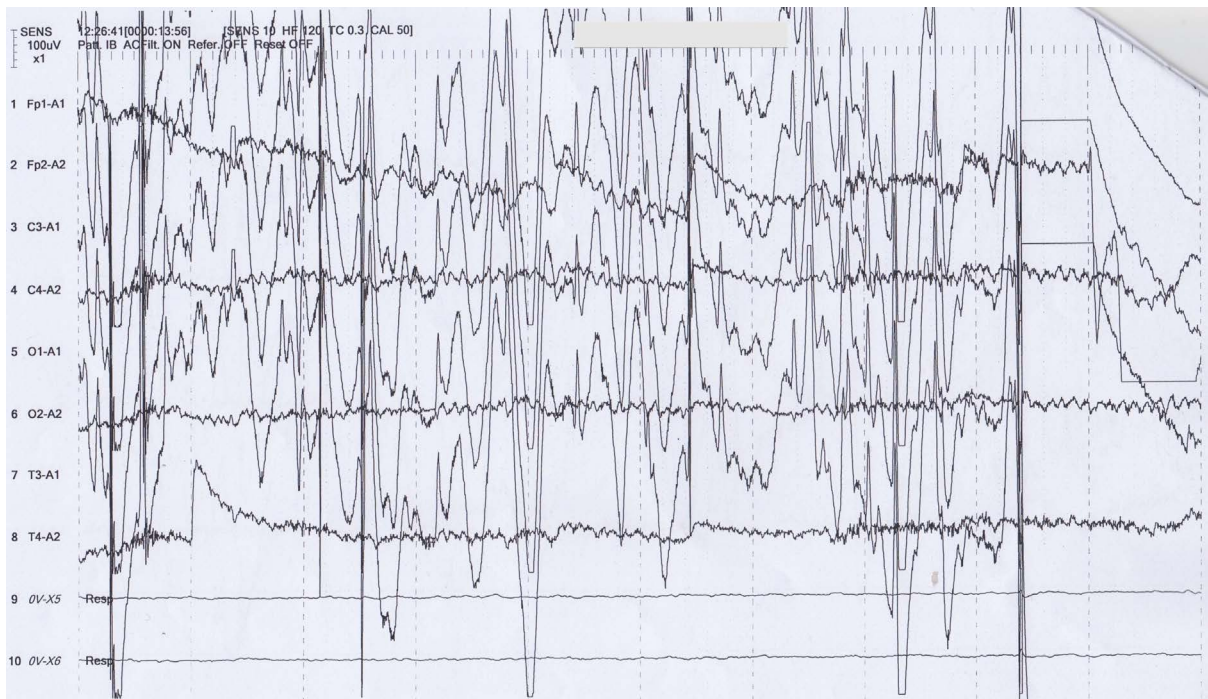

Figure 3. EEG report showing Epileptic activity after cough.

Several studies reported that any aura involved with epilepsy was developed mostly in a mesial temporal epilepsy. A study showed that majority of their patients with a mesial temporal epilepsy developed some sort of somatosensory aura mostly in the form of a tingling sensation in the upper extremities [5]. The study based on abdominal aura showed that development of an abdominal aura was more common in patients with temporal lobe epilepsies compared to those patients with an extra temporal epilepsy. Among the temporal lobe epilepsies

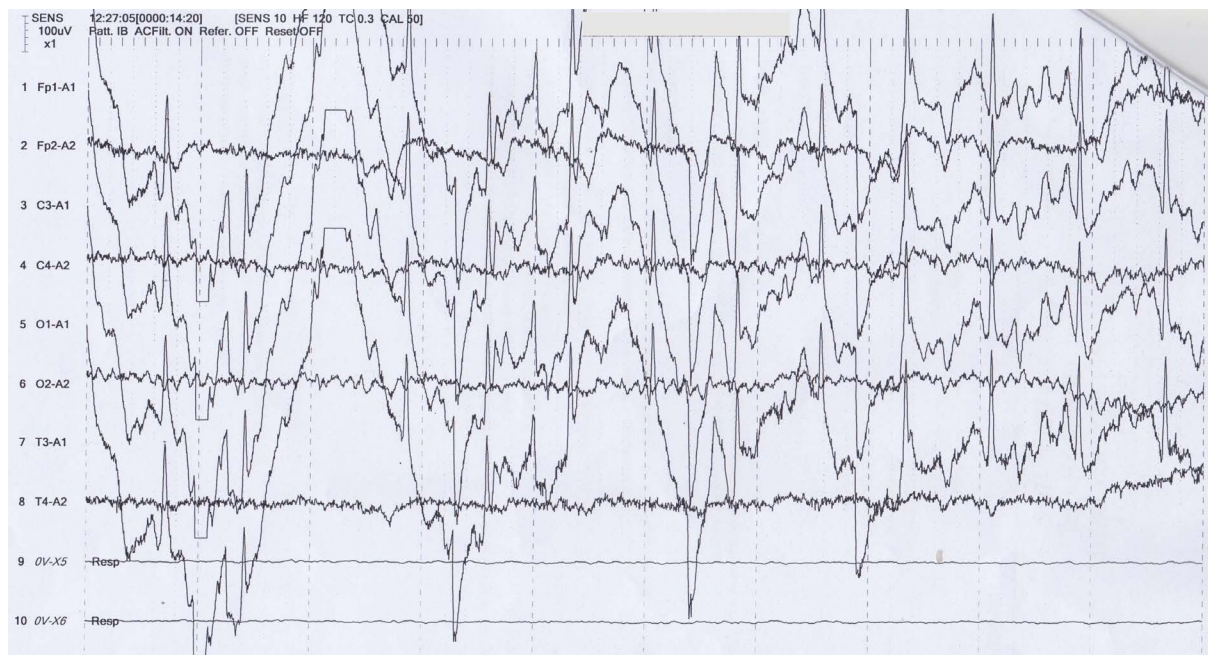

Figure 4. EEG report showing Epileptic activity after cough.

it was also reported that aura was more common in mesial temporal epilepsy than neocortical epilepsy [4]. The study based on olfactory aura reported that their patients MRI scans revealed structural lesions in the mesial temporal structures and two of their patient's scans even revealed structural lesions in the amygdale [3].

The presentation of Epilepsy with a cough aura is uncommon and not many studies report of similar cases. For this reason, it is essential that more research must be done, as it is highly probable that Epilepsy can present with other unusual symptoms besides cough.

4. Conclusion

Epileptic seizures are transient occurrences of signs and/or symptoms due to abnormal excessive or synchronous neuronal activity in the brain. The patient in this case lost consciousness after hyperventilation with severe cough followed by development of a tonic-clonic jerk of the right arm, which lasted for around 60 seconds. MRI revealed bilateral basal ganglia calcifications with bilateral maxillary and left ethmoid sinusitis along with hypertrophied left inferior nasal turbinate. Frequency of the attacks decreased dramatically with nebulization, antibiotics, steroids and anti-epileptics. There have been many studies showing epilepsy with somatosensory, olfactory and abdominal auras, but not particularly with cough. More evidence-based research must be conducted with regard to this case presentation.

References

- [1] <http://www.epilepsy.com/article/2014/4/revised-definition-epilepsy>
- [2] Erickson, J.C., Clapp, L.E., Ford, G. and Jabbari, B. (2006) Somatosensory Auras in Refractory Teemporal Lobe Epilepsy. *Epilepsia*, **47**, 202-206. <http://dx.doi.org/10.1111/j.1528-1167.2006.00388.x>
- [3] Chen, C., Shih, Y.H., Yen, D.J., Lirng, J.F., Guo, Y.C., Yu, H.Y. and Yiu, C.H. (2003) Olfactory Aura in Temporal Lobe Epilepsy. *Epilepsia*, **44**, 257-260. <http://onlinelibrary.wiley.com/doi/10.1046/j.1528-1157.2003.25902.x/pdf>
<http://dx.doi.org/10.1046/j.1528-1157.2003.25902.x>
- [4] Henkel, A., Noachtar, S., Pfander, M. and Luders, H.O. (2002) The Localizing Value of the Abdominal Aura and Its Evolution. *Neurology*, **58**, 271-276.
- [5] Rahal, M.A., Filho, G.M.A., Caboclo, L.O.S.F., Rosa, V.P., Centeno, R.S., Carrete Jr., H., Garzon, E., Sakamoto, A.C. and Yacubian, E.M.T. (2006) Somatosensory Aura in Mesial Temporal Lobe Epilepsy: Semiologic Characteristics, MRI Findings and Differential Diagnosis with Parietal Lobe Epilepsy. *Journal of Epilepsy and Clinical Neurophysiology*, **12**, 155-160. <http://dx.doi.org/10.1590/S1676-26492006000500008>

Scientific Research Publishing (SCIRP) is one of the largest Open Access journal publishers. It is currently publishing more than 200 open access, online, peer-reviewed journals covering a wide range of academic disciplines. SCIRP serves the worldwide academic communities and contributes to the progress and application of science with its publication.

Other selected journals from SCIRP are listed as below. Submit your manuscript to us via either submit@scirp.org or **Online Submission Portal**.

